Safety assessment of *Spondias purpurea* aqueous leaf extract (anacardiaceae): Acute and sub-chronic toxicity studies in wistar rats

Oluwaiye Jonah Omonofa[1*], Shehu Aishatu[1], Ibrahim Muazzamu Aliyu[1], Helen Ochuko Kwanashie[2], Sherifat Bola Anafi[1], Ibrahim Abubakar[1]

[1]Department of Pharmacology and Therapeutics, Ahmadu Bello University, Nigeria
[2]Department of Nursing Science, Faculty of Health Sciences, National Open University of Nigeria, Abuja, Federal Capital Territory, Nigeria

Submitted: 8th Jan., 2023; Accepted: 12th Feb., 2023; Published: 28th Feb., 2023
DOI: https://doi.org/10.54117/jcbr.v3i1.2
**Corresponding author: Oluwaiye Jonah Omonofa; jonaholuwaiye@gmail.com;+234-703-2147617*

Abstract

This study aimed to assess the toxicological profile of aqueous leaf extract of *S. purpurea* (ALES) in Wistar rats. ALES was subjected to acute and sub-chronic toxicity studies which were conducted according to Lorke's and Organization for Economic Co-operation and Development 408 guidelines respectively. The acute toxicity study was carried out in two phases within 48 hours. Sub-chronic (90 days) toxicity studies were conducted on 4 groups of rats each. The first group received 1mL/kg distilled water, Groups 2, 3 and 4 received ALES 250, 500 and 1000 mg/kg respectively. Preliminary phytochemical screening revealed the presence of saponins, steroids/triterpenes, flavonoids, tannins, alkaloids, and cardiac glycosides. The oral median lethal dose (LD_{50}) of the extract in rats was established to be greater than 5000 mg/kg. Sub-chronic administration of ALES did not produce significant changes in body weights and relative organ weights of treated rats. Hematology results between control and treated groups for a 90-day period of administration of ALES were comparable, however there was a significant ($p < 0.05$) increase in differential white blood cell at highest dose. Biochemical result, revealed a non-significant mean variations in levels of renal and hepatic parameters between the treated groups and their corresponding controls. However, there was a significant ($p < 0.05$) dose dependent decrease in level of potassium and glucose for treated groups compared their respective control, also a non-dose dependent decrease in ALP at 500 mg/kg ALES group. Lipid parameters examined also showed a dose dependent decrease in cholesterol, triglyceride, and LDL level, however the decrease was significant for triglyceride at 500 mg/kg and 1000 mg/kg treatment group compared to control. Additionally, in comparison to control a non-significant increase in HDL level was observed for treatment groups. The Histological result showed slight alterations in brain, liver, kidney, lungs and uterus intensified with an increase in the doses of the extracts administered. These findings suggest that *Spondias purpurea* leaf extract is

relatively safe on acute administration. However, long term administration of higher doses could result in mild toxic responses. Therefore, caution should be taken in long term administration of the extract.

Keywords: *Spondias purpurea*, Toxicity studies, Hematology, Biochemical, Histology

1. Introduction

Knowledge of traditional uses of medicinal plants by indigenous people plays a significant role and contribution to the search for new bioactive compounds for treating various diseases would be impossible for man without the use of such medicinal plants (Süntar, 2020). As defined by the World Health Organisation (WHO), a medicinal plant is any plant that in one or more of its organs contains substances that can be used for therapeutic purposes or which are precursors for the synthesis of useful drugs. The majority of people in developing countries rely on traditional healing practices and medicinal plants for their daily healthcare needs due to ease of accessibility, affordability and availability (Okpuzor *et al*., 2015, 2021). Medicinal plants, as well as synthetic drugs, have pharmacologically active principles responsible for the desired therapeutic effect in the body, thus, it becomes necessary to know the composition of the constituents of each plant and assessment of toxicity and their therapeutic potential (Bose *et al.*, 2021). The widespread conception among the population that "natural" means "safe" and that drugs of natural origin are harmless without any associated risk, does not match reality (David *et al*., 2015; Oluwaiye *et al*., 2020). Medicinal plants have inherent toxicity and herbal medicines, like any medicine, have side effects that can cause many diseases (Bernstein *et al*., 2021). *Spondias purpurea* L. is a flowering plant in the Anacardiaceae family, it is indigenous to tropical South America but has now been naturalized in countries like Nigeria and the Philippines. In Nigeria, the plant is grown in the central northern part of the country where it is referred to as Iyeye by the Okuns, Osinkara by the Ebira, and Jinjere by the Nupe people (Elufioye and Berida, 2018).The plant has been in continuous use for different purposes, such as nutritional, medicinal, and agriculture. In Nigeria, the plant is used in the form of fresh leaves infusion as a remedy for stomachache and flatulence (Alfaro, 1984; Elufioye and Berida, 2018). Decoction of the leaves and bark is used for anemia, diarrhea, dysentery, lowering cholesterol and skin infections. However, no in-depth toxicity study on sub-chronic administration of any part of *Spondias purpurea* had been reported. This investigation aimed to evaluate the possible effect of sub-chronic administration of the aqueous leaf extract of *Spondias purpurea* in Wistar rats.

2. Materials and methods

2.1. Animals

Female Wistar rats (120-150 g) were sourced from the Animal House Facility of the Faculty of Pharmaceutical Sciences, Ahmadu Bello University (A.B.U.), Zaria, Nigeria. They were managed in well-ventilated cages at room temperature under a normal day and night cycle and were maintained on standard laboratory animal diet with water *ad libitum*. The animals were treated in accordance with the NIH Guide for the Care and Use of Laboratory Animals. Ethical clearance was obtained for the experimental protocols from the Ahmadu Bello University Committee on Animal Use and Care (ABUCAUC) with approval number ABUCAUC/2022/025

2.2. Plant Materials

For identification the fresh stem of *Spondias purpurea* along with its fruits and leaves was collected at the Institute of Agricultural Research, Ahmadu Bello University Zaria, Kaduna State, Nigeria in the month of May 2021. It was identified and authenticated by Mr. Sanusi Namadi, a taxonomist with the Department of Botany, Ahmadu Bello University, Zaria, Kaduna, by comparing it with the existing specimen voucher number ABU2384.

2.3. Plant Extraction

For extraction, the fresh leaves obtained were shade dried with intermittent weighing until a constant weight was obtained. The dried materials were pulverized with the aid of a mortar and pestle to form coarse powder of the leaves material for effective extraction. Thereafter, 0.72 kg of the powdered plant was extracted by cold maceration using distilled water (1.5 L) for 24 hours with occasional shaking in the Department of Pharmacognosy and Drug Development, Ahmadu Bello University, Zaria. The extract obtained was subsequently concentrated over a freeze dryer (Beijing Songyuanhuaxing Tech. LGJ-12) at the National Research Institute for Chemical Technology (NARICT), Zaria. The dried extract was weighed and labeled as an aqueous leaf extract of *S. purpurea* (ALES). It was kept in a desiccator at room temperature (25±1.5 ºC) until needed for use.

2.4. Phytochemical Screening

ALES was subjected to qualitative phytochemical screening using simple chemical tests as described by Trease and Evans, (2002).

2.5. Preparation of extract and treatment

Different stock solutions of ALES were prepared using distilled water, followed by serial dilution to obtain the exact experimental concentrations needed. The solutions were freshly prepared daily and orally administered with the aid of oral gavages.

2.6. Acute Toxicity Study

Determination of acute toxicity of ALES was carried out by the method of Lorke (1983) in two phases. In phase 1; nine rats were divided into three groups and were administered 10, 100 and 1000 mg/kg of the extract orally respectively. The animals were observed for 24 hours and no death was recorded, thus the second phase was conducted. In the second phase**,** three rats were given ALES extract at dose 1600, 2900 and 5000 mg/kg each and were observed for 24 hours also. The median lethal dose was then determined.

2.7. Sub-chronic Toxicity Study

The study was conducted according to OECD 408 guidelines (2018). Twenty rats were fasted overnight and then divided into four groups of five rats each. The first group served as a control and received distilled water 1 mL/kg. The 2nd, 3rd and 4th groups were administered ALES at doses of 250, 500 and 1000 mg/kg by 10:00 AM daily for 90 days. The mortality and general behaviour of the rats were observed daily and their body weights recorded weekly. The rats were then euthanized using mild diethyl ether on the 90th day of the experiment and their organs and blood samples were collected for further investigations.

2.8. Hematological analysis

Blood samples for haematological evaluation were collected into ethylene diamine tetra-acetic acid sample bottles. Analysis was carried out using automated haematology machine (Cell-Dyn, Abbott, USA). The levels of red blood cell (RBC) count, haemoglobin (HGB), haematocrit (HCT), mean corpuscular volume (MCV), mean corpuscular haemoglobin (MCH), mean

corpuscular haemoglobin concentration (MCHC), platelet (PLT), white blood cell (WBC) count, lymphocytes (LYM), granulocytes (GRAN), monocytes (MXD), neutrophils (NEU), eosinophils and basophils were determined.

2.9. Biochemical analysis

Blood for biochemical analysis was collected in plain bottles and centrifuged at 3500 revolutions per minute (rpm) for 10 minutes to obtain serum and were investigated to estimate the effect of ALES on biochemical indices using photoelectric colorimeter (AC-115 Optima, Japan). Biochemical parameters such as alanine transaminase (ALT), aspartate transaminase (AST), alkaline phosphatase (ALP) (Reitman and Frankel,1957), albumin, total bilirubin, direct bilirubin (Walters and Gerarde, 1970), total protein, albumin (Doumas *et al*., 1997) urea, creatinine, electrolytes (Heinegard and Tiderstrom, 1973), cholesterol, triglycerides, high-density lipoproteins (HDL), low-density lipoprotein (LDL) and glucose (Friedewald *et al*.,1972; Allain *et al*., 1974).

2.10. Histological study

At the end of the treatment period for each study, each rat was weighed, and the liver, kidney, lung, heart, stomach, and small intestine of the animals were removed and weighed. The relative organ weight (ROW) was calculated by expressing the absolute organ weight as a percentage of total body weight using the following formula:

$$\text{Relative Organ Weight (\%)} = \frac{\text{Organ Weight (g)}}{\text{Final Body Weight (g)}} \times 100$$

The organs were processed for embedment in paraffin wax after fixation in 10% formalin. Sections from the liver, kidney, heart, lung, stomach and small intestine were cut 4-5µm with rotary microtone, stained with hematoxylin and eosin, and examined by light microscopy (Rolls, 2011). The photomicrographs were observed for any histopathological changes.

2.11. Statistical Analysis

Data generated from the experiments were entered into SPSS software. Descriptive statistics were carried out to obtain the mean ± SEM. Data on relative organ body weight, hematological, hepatic, and renal indices were analyzed using one-way analysis of variance (ANOVA) while those of body weight were analyzed using split plot ANOVA followed by Dunnett's post-hoc test for multiple comparison. Statistical significance was considered at $p < 0.05$.

3. Results

3.1 Extractive value and phytochemical constituents

The aqueous leaf extract of *S. purpurea* was found to be gummy in nature with a honey-like aroma. The extraction of 720.40 g of the powdered plant material produced 142.06 g of the extract corresponding to a yield of 19.73 %. Phytochemical constituents found present in ALES were flavonoids, alkaloids, steroids/triterpenes, saponins, glycosides and cardiac glycosides.

3.2 Median lethal dose of ALES (LD_{50})

Oral administration of ALES produced no visible signs of toxicity and mortality throughout the study period. The LD_{50} was found to be > 5 000 mg/kg.

3.3 Effect of 90-days daily oral administration of ALES on general behaviour and mortality

Administration of ALES orally (250, 500 and 1000 mg/kg) neither produced observable signs and symptoms of toxicity nor mortality.

3.4 Effect of 90-days daily oral administration of aqueous leaf extract of S. purpurea on body weights of rats

The oral administration of ALES did not produce any significant ($p > 0.05$) changes in the body weights of the rats when compared to the control group (Figure 1).

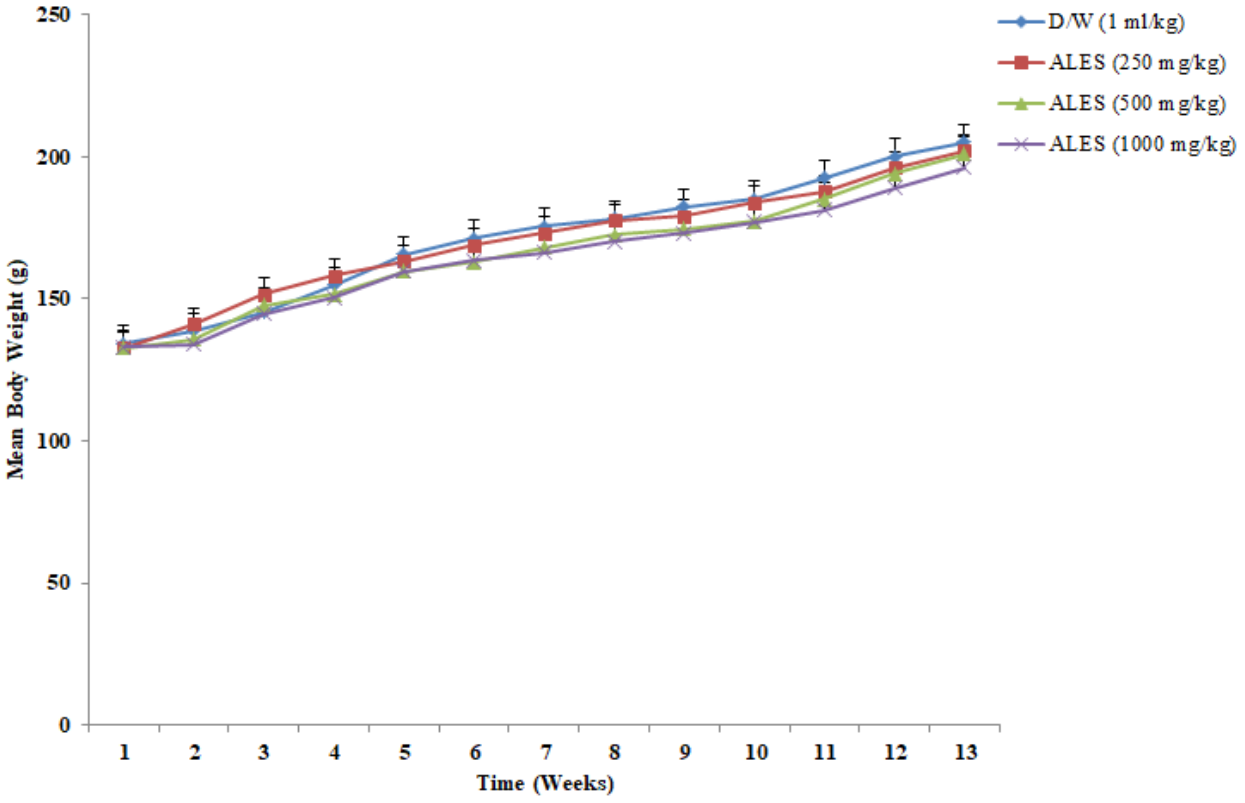

Figure 1: Effect of 90-days Daily Oral Administration of Aqueous Leaf Extract of *S. purpurea* on Body Weights of Rats

Values are expressed as Mean ± S.E.M, Data analyzed using split plot ANOVA, n=5, D/W = Distilled water, ALES = Aqueous leaf Extract of *S. purpurea*

3.5 Effect of 90-days daily oral administration of ALES on relative organ-body weights

Oral administration of ALES neither produce significant ($p > 0.05$) increase nor decrease in the relative organ/body weights as compared to the control group (Table 1)

Table 1: Effect of 90-days daily oral administration of aqueous leaf extract of *Spondias purpurea* on relative organ weight of rats

Organ	Mean Weight (g)			
	D/W (1mg/kg)	ALES (250 mg/kg)	ALES (500 mg/kg)	ALES (1000 mg/kg)
Brain	0.93 ± 0.03	0.83 ± 0.02	0.85 ± 0.03	0.81 ± 0.02
Heart	0.37 ± 0.03	0.35 ± 0.04	0.45 ± 0.07	0.40 ± 0.04
Intestine	3.68 ± 0.11	3.64 ± 0.21	3.50 ± 0.31	3.66 ± 0.16
Kidney	0.64 ± 0.01	0.71 ± 0.07	0.65 ± 0.03	0.64 ± 0.03
Liver	3.57 ± 0.1	3.47 ± 0.13	3.17 ± 0.21	3.34 ± 0.01
Lungs	1.06 ± 0.04	1.12 ± 0.08	1.12 ± 0.08	1.14 ± 0.06
Spleen	0.45 ± 0.03	0.44 ± 0.03	0.42 ± 0.04	0.41 ± 0.05
Stomach	1.29 ±0.06	1.75 ± 0.16	1.37 ± 0.07	1.44 ± 0.14
Uterus	0.51 ± 0.04	0.47 ± 0.05	0.52 ± 0.06	0.54 ± 0.06

Values are expressed as Mean ± S.E.M.; No significant differences compared to D/W group, n=5, D/W = Distilled water, ALES = Aqueous leaf Extract of *S. purpurea.*

3.6 Effect of 90-days daily oral administration of ALES on hematological parameters

The administration of ALES did not show any significant ($p > 0.05$) difference in WBC count, percentage of lymphocytes, RBC, HGB, HCT, MCV, MCH and MCHC. However, a significant ($p < 0.05$) increase in the percentage of eosinophils, basophils and monocytes was observed in the group treated with 1,000 mg/kg dose of extract (Table 2).

Table 2: Effect of 90-Days Oral Administration of Aqueous Leaf Extract of *Spondias purpurea* on Hematological Parameters of Rats

Hematological Parameters	Treatments (mg/kg)			
	D/W (1ml/kg)	ALES (250)	ALES (500)	ALES (1000)
WBC($x10^9$/L)	4.10 ± 0.36	4.71 ± 0.74	4.74 ± 0.36	4.96 ± 0.80
LYM(%)	56.10 ± 2.26	60.32 ± 4.22	58.48 ± 3.24	49.28 ± 3.12
MID(%)	5.12 ± 0.59	7.26 ± 1.67	9.26 ± 0.68	10.25 ± 1.53*
GRAN(%)	39.74 ± 1.96	35.20 ± 2.50	37.36 ± 3.51	37.96 ± 3.41
RBC($x10^{12}$/L)	5.82 ± 0.15	5.78 ± 0.19	5.74 ± 0.25	6.14 ± 0.19
HGB(g/dL)	12.96 ±0.75	12.04 ± 0.38	13.16 ± 1.16	12.34 ± 0.29
HCT(%)	38.20 ± 2.05	35.40 ± 0.94	35.00 ± 0.77	37.20 ± 0.86
PLT($x10^9$/L)	191.20 ± 28.69	210.20 ± 17.57	206.20 ± 18.47	204 ± 25.84
MCV(fL)	88.64 ± 2.89	91.82 ± 1.65	86.98 ± 2.40	89.38 ± 0.94
MCH(pg)	29.76 ± 0.31	30.10 ± 0.11	30.26 ± 0.16	30.20 ± 0.10
MCHC(g/dL)	33.82 ± 0.29	34.28 ± 0.49	34.40 ± 0.36	35.28 ± 0.52

Data were presented as Mean ± SEM;*$p < 0.05$= significant difference as compared to the control group (One Way ANOVA followed by Dunnett's post hoc test), DW= Distilled water, ALES= Aqueous leaf extract of *S. purpurea*, WBC= White blood cell count, LYM %= Percentage of lymphocytes, MID %= Percentage of eosinophils, basophils and monocytes, GRA %= Percentage of granulocytes, RBC= Red blood cell count, HGB= Haemoglobin, HCT= Haematocrit, PLT=

Platelet, MCV= Mean corpuscular volume, MCH= Mean corpuscular haemoglobin, MCHC= Mean corpuscular haemoglobin concentration, n=5

3.7 Effect of 90 days daily oral administration of ALES on levels of biochemical markers of liver function in Wistar rats

Following 90-days oral administration of ALES, no significant ($p > 0.05$) difference in hepatic biomarkers such as ALT, AST, total protein, albumin, total bilirubin, and direct bilirubin. However, a significant ($p < 0.05$) reduction in glucose was observed in the treatment groups, also ALP at 500 mg/kg of the extract as compared to their respective control. (Table 3).

Table 3. Effect of 90 Days Daily Oral Administration of ALES on Levels of Biochemical Markers of Liver Function in Wistar Rats

Treatment (mg/kg)	**Hepatic Parameters**							
	ALT (I.U/L)	**AST (I.U/L)**	**ALP (I.U/L)**	**TP (mg/dL)**	**ALB (mg/dL)**	**TB (mg/dL)**	**DB (mg/dL)**	**GLU (mg/dL)**
D/W 1ml/kg	7.60 ± 1.57	101.21±22.88	29.30±2.39	4.30±0.66	2.10±0.29	12.58±1.33	6.16±0.60	102.67±1.80
ALES 250	7.20 ± 1.02	89.00 ± 9.55	25.54 ± 1.16	4.22 ± 0.71	2.06 ±0.27	16.20 ± 2.13	8.70 ± 1.75	78.33 ± 0.96*
ALES 500	8.40 ± 2.20	102.10 ± 11.33	15.92 ± 0.80*	4.22 ± 0.71	1.94 ±0.23	16.54 ± 2.50	9.62 ± 1.46	72.00 ± 0.71*
ALES 1000	8.80 ± 1.46	94.00 ± 22.49	22.52 ± 1.79	3.34 ± 0.34	1.64 ±0.13	16.66 ± 1.80	9.92 ± 1.37	51.83 ± 2.68*

Data are presented as Mean ± SEM; *$p < 0.05$= significant difference as compared to the control group (One Way ANOVA followed by Dunnett's post hoc test), DW= distilled water, ALES= Aqueous leaf extract of *S. purpurea*, ALT= Alanine transaminase, AST= Aspartate transaminase, ALP= Alkaline Phosphatase, TP= Total Protein, ALB= Albumin, TB= Total Bilirubin, DB= Direct Bilirubin, GLU= Glucose, n=5

3.8 Effect of 90 days daily oral administration of ALES on levels of biochemical markers of kidney function in Wistar rats

The 90-days administration of ALES showed insignificant ($p > 0.05$) change in renal parameters such as urea, creatinine, sodium, chlorine, and bicarbonate. However, there was a significant ($p < 0.05$) and dose-dependent decrease in potassium compared to the control group (Table 4).

Table 4. Effect of 90 Days Daily Oral Administration of ALES on Levels of Biochemical Markers of Kidney Function in Wistar Rats

Treatment (mg/kg)	**Renal Parameters**					
	Urea (mmol/L)	Creatinine (mmol/L)	Sodium (mmol/L)	Potassium (mmol/L)	Chloride (mmol/L)	Bicarbonate (mmol/L)
D/W1ml/kg	31.4 ± 3.90	0.78 ± 0.10	76.90 ± 2.30	20.94 ± 1.15	30.00 ± 1.48	77.80 ± 5.40
ALES 250	40.11 ± 4.23	0.80 ± 0.14	55.92 ± 3.48	8.96 ± 0.89*	27.40 ± 3.54	82.20 ± 3.49
ALES 500	41.02 ± 3.44	1.00 ± 0.05	54.72 ± 2.32	8.14 ± 0.11*	21.20 ± 2.76	86.60 ± 2.61
ALES 1000	40.91 ± 3.44	0.92 ± 0.10	69.04 ± 4.20	5.73 ± 1.46*	22.60 ± 1.50	85.60 ± 2.22

Data are presented as Mean ± SEM; * $p < 0.05$= significant decrease as compared to the control group (One Way ANOVA followed by Dunnett's post hoc test), DW= distilled water, ALES= Aqueous Leaf Extract of S. *purpurea*, n=5

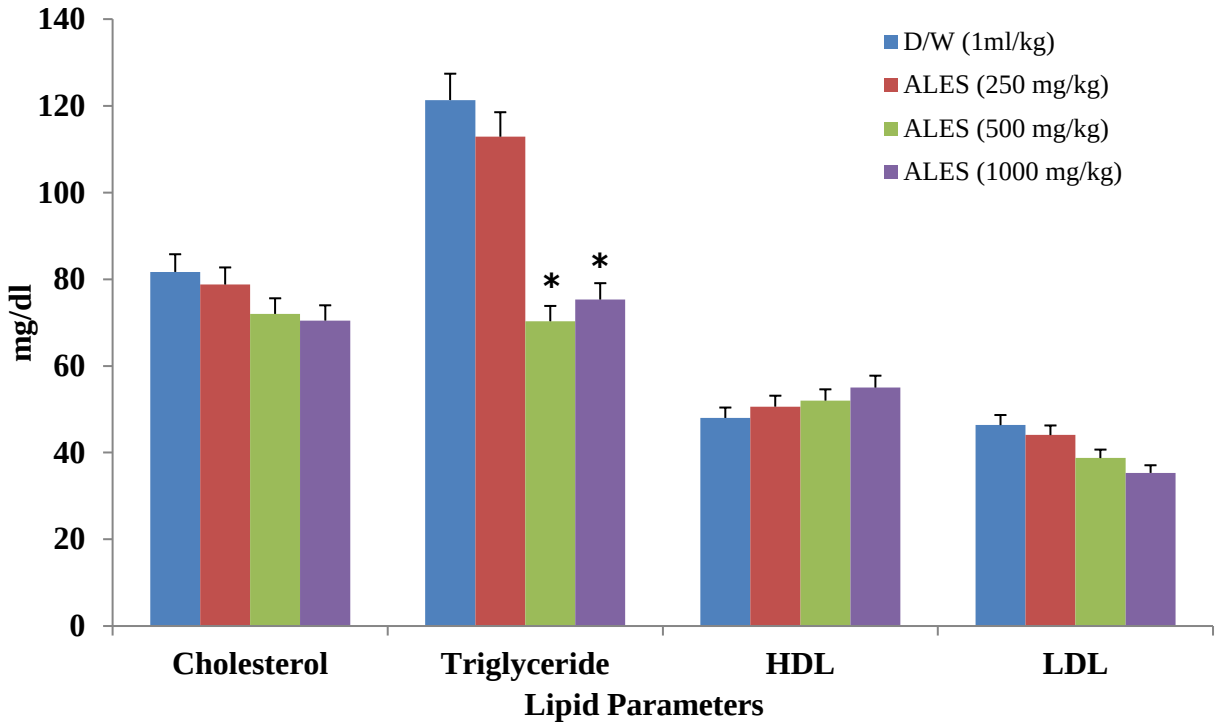

Figure 2: Effect of 90-Days Daily Oral Administration of Aqueous Leaf Extract of *Spondias purpurea* on Lipid Profile of Rats

Data are presented as Mean ± SEM; * $p < 0.05$= significant difference as compared to control group (One-way ANOVA followed by Dunnett's post hoc test), DW= distilled water, ALES= Aqueous leaf extract of *S. purpurea*, LDL= Low-Density Lipoprotein, HDL= High-Density Lipoprotein, n=5

4.1 Effect of 90-Days Oral Administration of Aqueous Leaf Extract of *Spondias purpurea* on Histology of Some Rats Organs

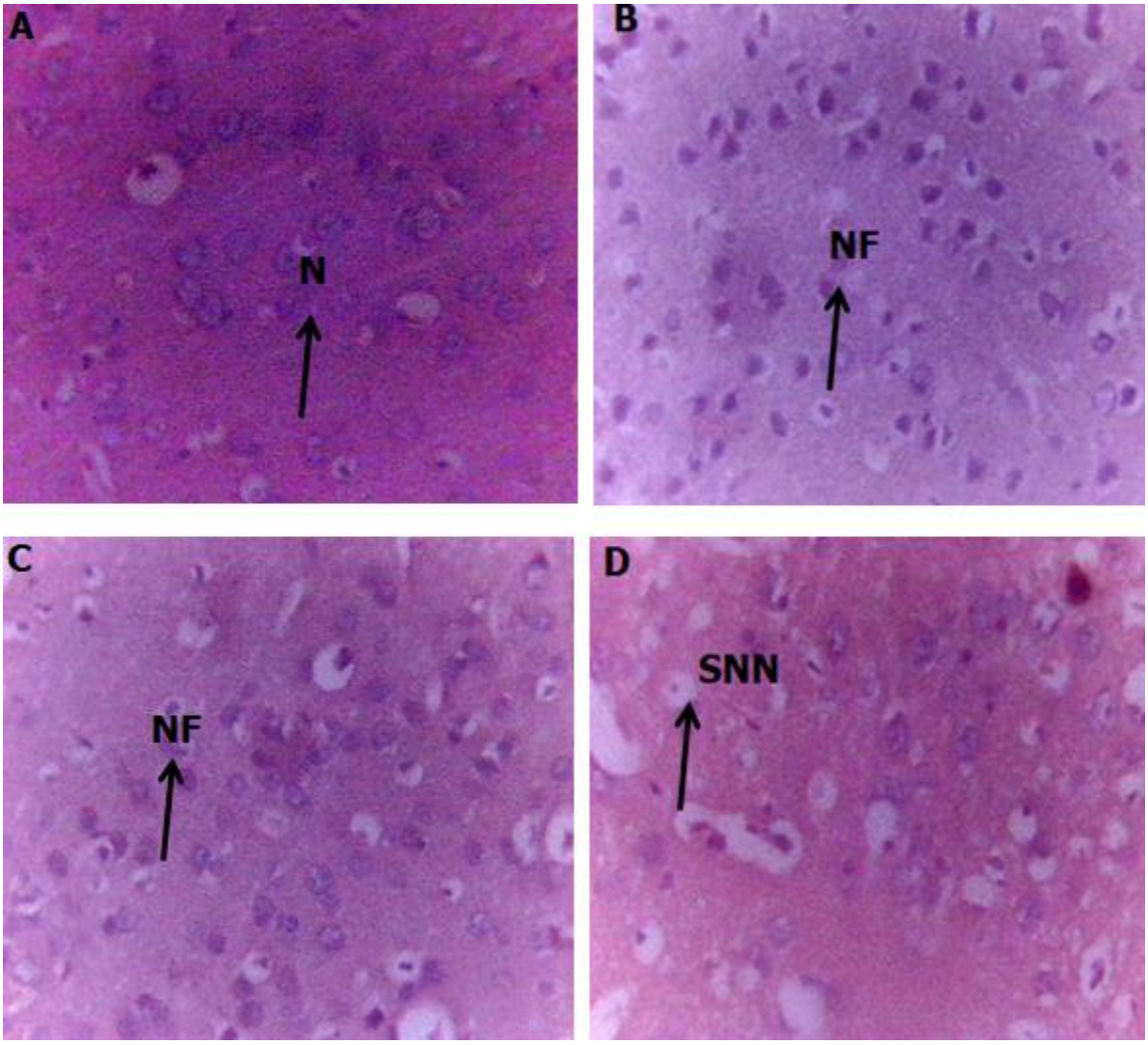

Plate I: Photomicrogram of Brain Sections from Rats Orally Treated Daily with Aqueous Leaf Extract of *Spondias purpurea* for 90-Days (H and E stained at ×250)

A) Control (Distilled water, 1 ml/kg), B) ALES (250 mg/kg), C) ALES (500mg/kg), D) ALES (1,000 mg/kg), N= Normal neuron, NF= Normal features of the brain, SNN= Slight neuronal necrosis, ALES= Aqueous leaf extract of *Spondias purpurea*

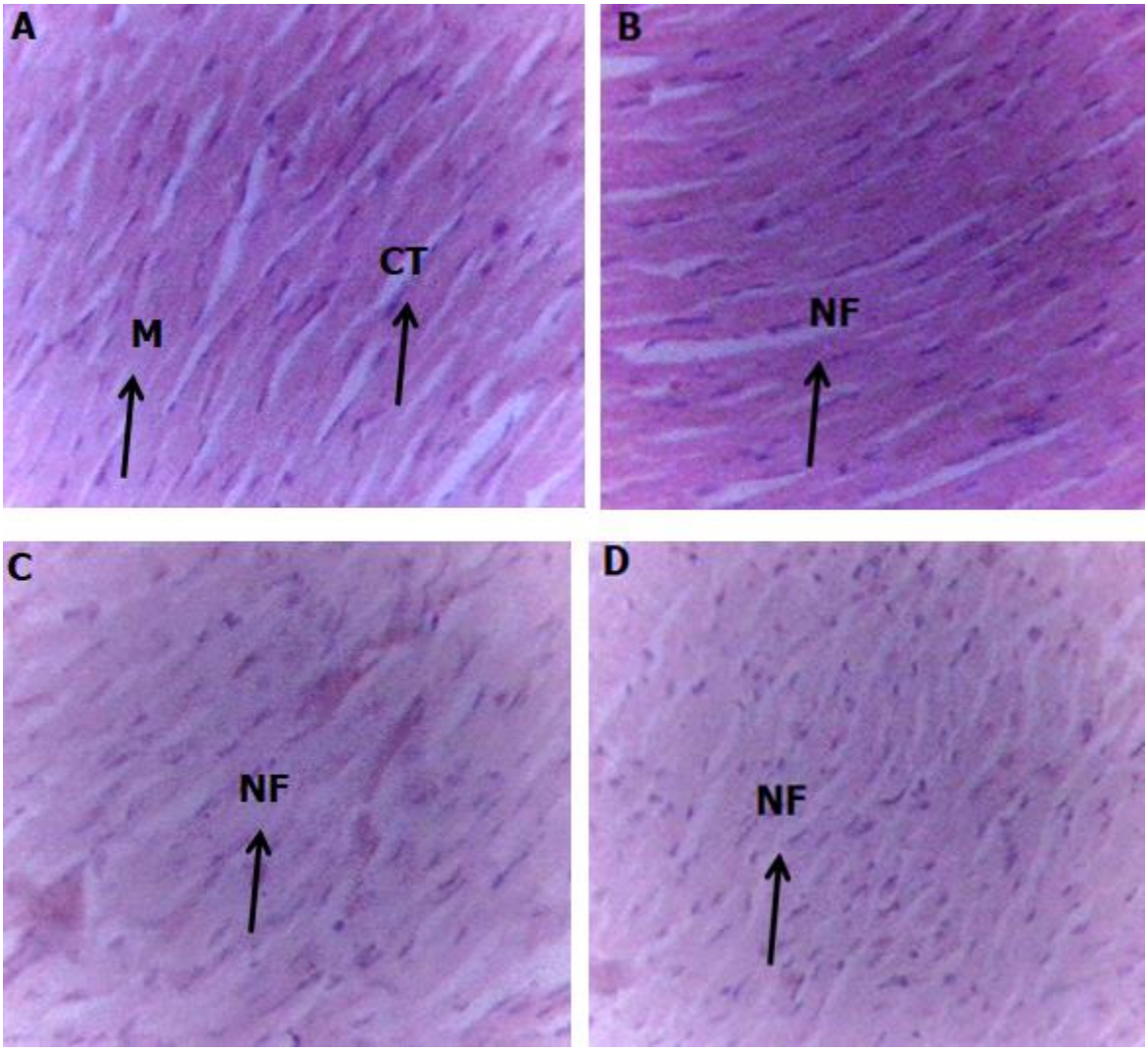

Plate II: Photomicrograms of Heart Sections from Rats Orally Treated Daily with Aqueous Leaf Extract of *Spondias purpurea* for 90-Days (H and E stained at ×250)

A) Control (Distilled water, 1 ml/kg), B) ALES (250 mg/kg), C) ALES (500 mg/kg), D) ALES (1,000 mg/kg), M= Normal myocardium, CT= Connective tissue, NF=Normal feature of the heart, ALES= Aqueous leaf extract of *Spondias purpurea*

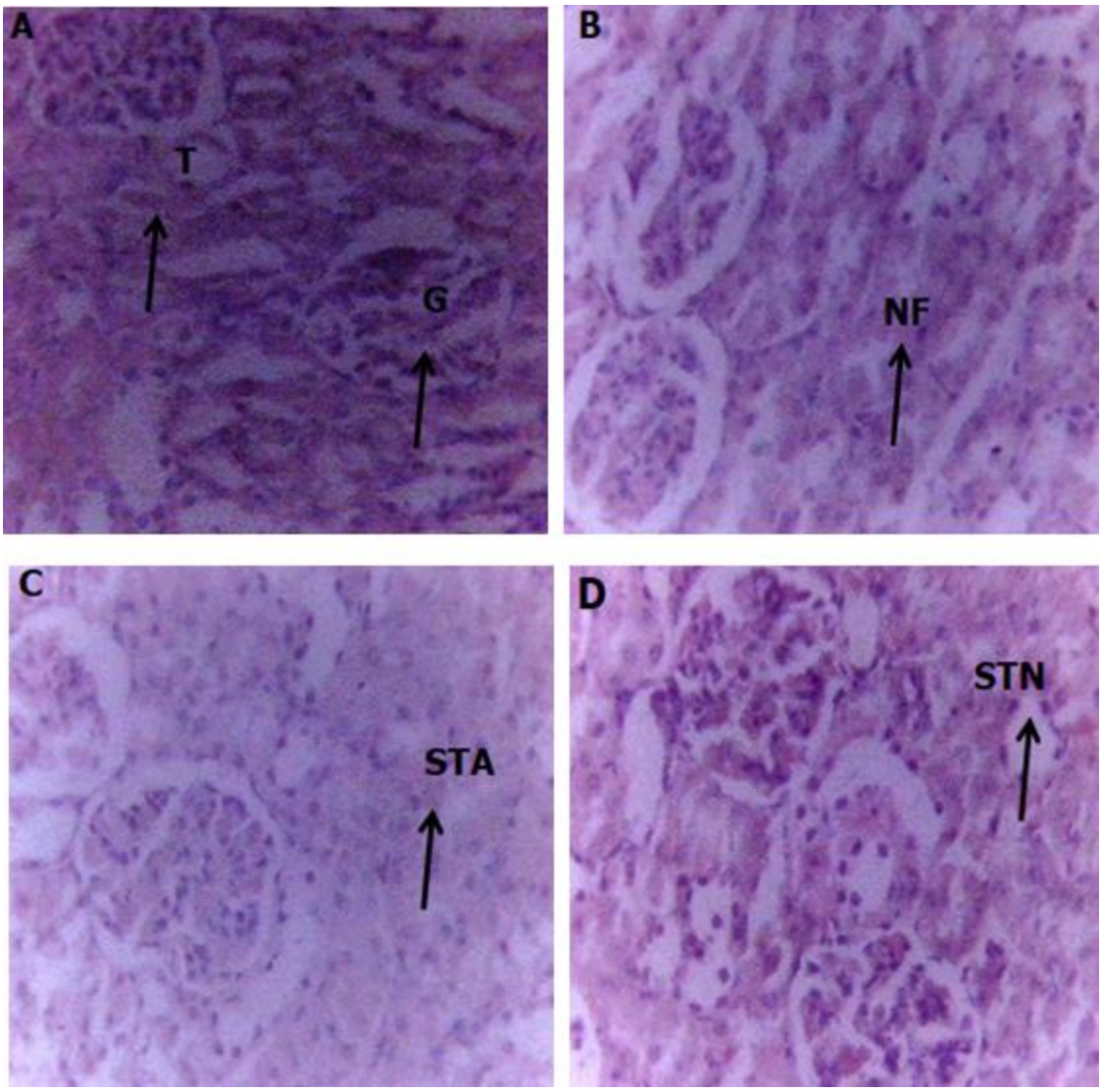

Plate III: Photomicrograms of Kidney Sections from Rats Orally Treated Daily with Aqueous Leaf Extract of *Spondias purpurea* for 90-Days (H and E stained at ×250)

A) Control (Distilled water, 1 ml/kg), B) ALES (250 mg/kg), C) ALES (500 mg/kg), D) ALES (1,000 mg/kg), G= Normal glomerulus, T= Normal tubules, NF=Normal renal features, STA= Slight tubular adhesion, STN= Slight Tubular necrosis, ALES= Aqueous leaf extract of *Spondias purpurea*

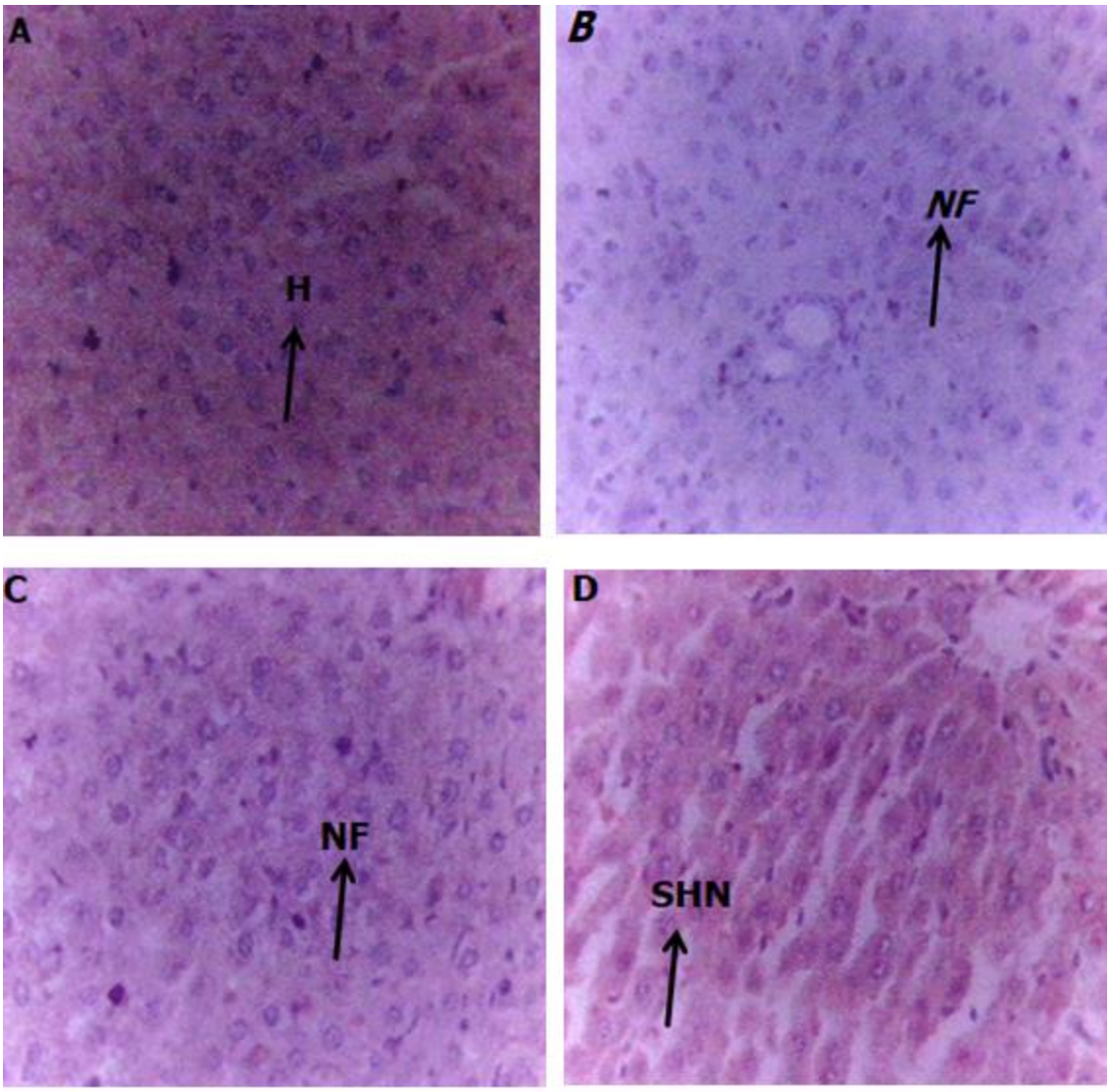

Plate IV: Photomicrograms of Liver Sections from Rats Treated Daily with Aqueous Leaf Extract of *Spondias purpurea* for 90-Days (H and E stained at ×250)
A) Control (Distilled water, 1 ml/kg), B) ALES (250 mg/kg), C) ALES (500 mg/kg), D) ALES (1,000 mg/kg), H= Normal Hepatocytes, NF= Normal features of the liver, SHN= Slight hepatic necrosis, ALES= Aqueous leaf extract of *Spondias purpurea*

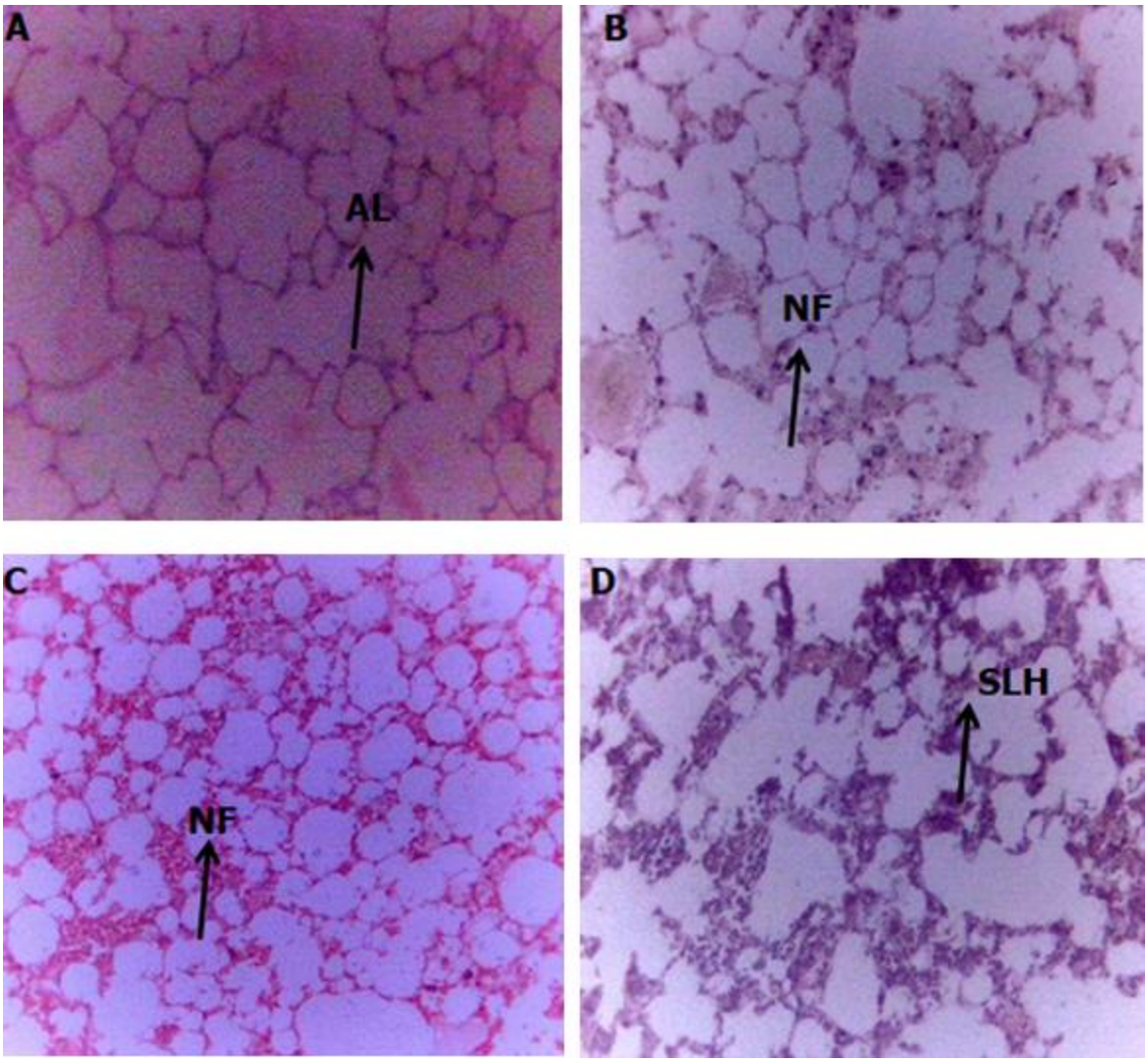

Plate V: Photomicrograms of Lung Sections from Rats Treated Daily with Aqueous Leaf Extract of *Spondias Purpurea* for 90-Days (H and E stained at ×250)

A) Control (Distilled water, 1 ml/kg), B) ALES (250 mg/kg), C) ALES (500 mg/kg), D) ALES (1,000 mg/kg), AL= Normal alveoli, NF= Normal features of the lungs, SLH= slight hyperplasia of inflammatory cell, ALES= Aqueous leaf extract of *Spondias purpurea*

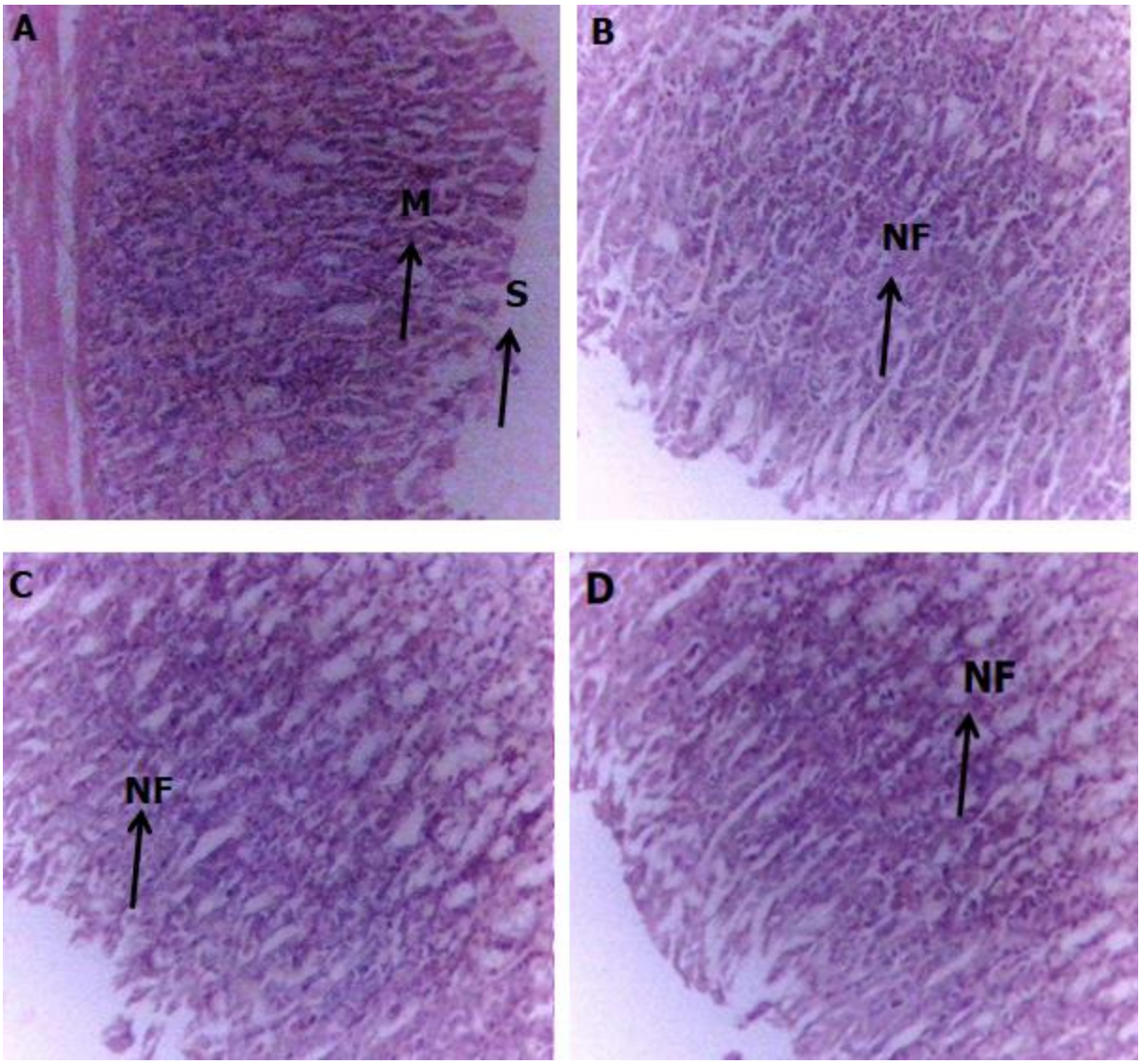

Plate VI: Photomicrograms of Stomach Sections from Rats Orally Treated Daily with Aqueous Leaf Extract of *Spondias Purpurea* for 90-Days (H and E stained at ×250)

A) Control (Distilled water, 1 ml/kg), B) ALES (250 mg/kg), C) ALES (500 mg/kg), D) ALES (1,000 mg/kg), ALES= Aqueous leaf extract of *Spondia spurpurea*, M= Normal mucosa, S= Serosa, NF = Normal features of the stomach.

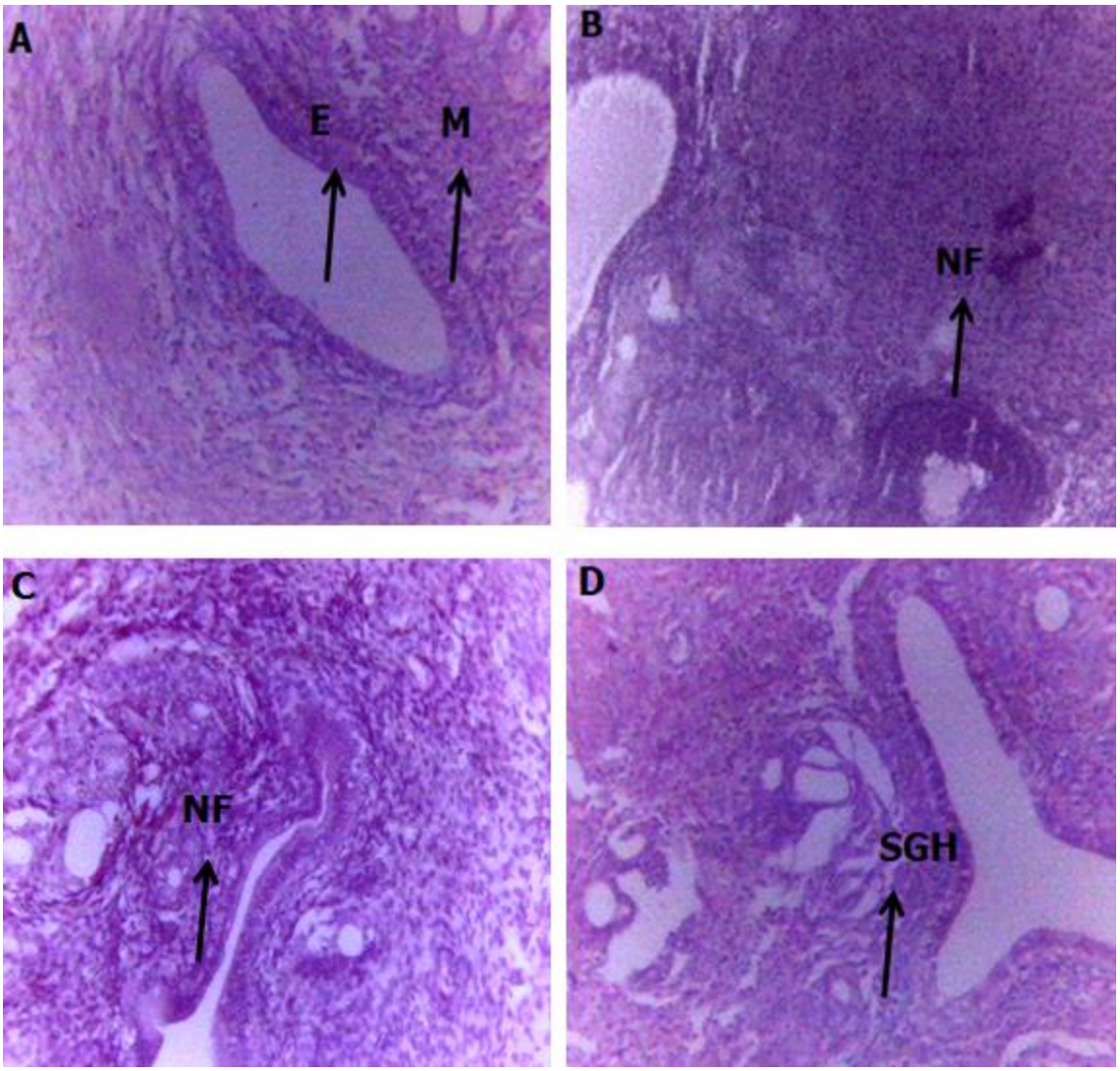

Plate VII: Photomicrograms of Uterus Sections from Rats Orally Treated with Aqueous Leaf Extract of *Spondias purpurea* for 90-Days (H and E stained at ×250)

A) Distilled water, 1 ml/kg B) ALES 250 mg/kg, C) ALES 500 mg/kg, D) ALES 1,000 mg/kg, E=Normal Endometrium, M =Normal Myometrium, NF= Normal features of the uterus, ALES= Aqueous leaf extract of *Spondias purpurea*

4. Discussion

The Use of Medicinal plants as a source of drugs has gained wide acceptability globally, especially in low and middle-income countries (Vaghasiya *et al*., 2011; Mensah *et al*., 2019). Medicinal plants contain varying pharmacologically bioactive constituents or highly active pharmacological compounds and this has been the basis for their use in the treatment of various diseases (Wang *et al*., 2014; Luo *et al*., 2019). Phytochemical screening is carried out to determine the presence of secondary metabolites in a plant which are responsible for the potential biological or harmful effects of these medicinal plants (Nandagoapalan *et al*., 2016). The phytochemical screening of the aqueous leaf extract of *Spondias purpurea* (ALES) revealed the presence of flavonoids, tannins, steroids and triterpene, saponins, alkaloids and cardiac glycosides. Previous studies have also shown the presence of the same phytochemical constituents which could be responsible for the observed pharmacological actions of the plant (Marisco and Pungartnik, 2015). Evaluation of acute toxicity of an unknown substance is the initial step for toxicological investigation, which involves the determination of median lethal dose (Saganuwan, 2017). However, acute toxicity data are of limited clinical application due to the fact that cumulative toxic effects could occur even at very low doses (Mabaku *et al*., 2007; Abotsi *et al*., 2011; Adegbola *et al.*, 2020). Hence, in this study, the sub-chronic toxicity profile of *Spondias purpurea* leaf extract was evaluated in rats using body and organ weights, haematological, biochemical and histological parameters.

The oral acute toxicity study neither show any toxic symptoms nor mortality at up to 5000 mg/kg of the extract in rats. On the basis of these observations, the oral median lethal dose of *Spondias purpurea a*queous extract was found to be greater than 5000 mg/kg body weight, thus suggesting that the extract is practically non-toxic when used orally for a short period of time (Lorke, 1983).

Changes in the body weight are sensitive indices of adverse effects of drugs and chemicals. Progressive changes in body weight may serve as an indication for the physiological state of an animal. Abnormal changes in body weight during drug administration have also been used as an indicator of the adverse effects of drugs and chemicals (Datta, 2012; Wang *et al.*, 2014; Abubakar *et al*., 2019). Daily oral administration of *S. purpurea* over the period of 90 days showed no significant changes in body weight in the treated rats as compared to the control as there was a steady and normal increase in the body weight of the rats in all the groups during the study. These results suggested that there was no alteration in the normal growth pattern of rats for sub-chronic oral administration of *S. purpurea* leaf extract. The findings in this study are comparable to the previous reported effects of the extract on body weight (Gara *et al*., 2021).

Organ weight is also an important index of the physiological and pathological status of an animal, the relative organ weight is fundamental to establishing whether or not the organ was exposed to injury, and could also indicate toxicity (Jothy *et al*., 2009; Yamssi *et al*., 2020). Organ weight result from this study shows the extract did not cause significant changes in organ weights of the rats since the weights for treatment groups were comparable to control.

The hematopoietic system is one of the sensitive targets for toxic compounds and an important index of physiological and pathological status in man and animals. Analysis of blood parameters is relevant in the assessment of toxicity, and changes in hematological parameters have a high

predictive value for human toxicity (Clark and Steger-Hartmann, 2018). The hematopoietic system is a susceptible target for toxic chemicals, especially in the bone marrow where the production of red blood cells occurs (Kifayatullah *et al*., 2015; Roland *et al*., 2022). In this research, sub-chronic administration of graded doses of ALES on hematological indices showed a significant increase in the percentage of eosinophils, basophils, and monocytes which also corroborates the slightly insignificant higher level of total WBC for treated group compare to the control, this could be an increase in innate immunity in response to slight toxic effects observed in some vital organs like kidney and liver. White Blood Cells play an important role in cellular defensive mechanisms in the body's response to infectious agents, tissue damage and inflammatory mechanism, suggesting that the extract may exert immune modulatory effect (Yuet Ping *et al*., 2013; Mitsios *et al*., 2020).

Analysis of biochemical parameters on experimental animals helps evaluate toxic effects on different tissues, especially the liver and kidney (Traesel *et al*., 2016). The liver's normal metabolic function is determined by serum hepatic biomarkers (El Kabbaoui *et al*., 2017). The liver and kidneys are crucial organs that perform a significant role in detoxification. Liver function tests involve evaluating serum alanine aminotransferase (ALT), aspartate aminotransferase (AST), alkaline phosphatase (ALP), bilirubin and albumin levels. The main organ for xenobiotics metabolism is the liver where compounds or hepatotoxic metabolites may be formed, an increase in the levels of liver enzymes (AST and ALT and ALP) is conventionally an indication of liver injury (Harizal *et al*., 2010; Abubakar *et al*., 2019). The most commonly used indicators of liver damage are alanine aminotransferase and aspartate aminotransferase (Ramaiah, 2007; Li and Xia, 2019). ALT is localized primarily in the cytosol of hepatocytes and is considered to be a more sensitive marker of hepatocellular damage than AST, and can provide a quantitative assessment of the degree of damage sustained by the liver (Ramaiah, 2007; Carbone and Strazzabosco, 2020). Bilirubin is a bye product of hemoglobin degradation associated with liver diseases such as jaundice, defective erythropoiesis, and cholestasis (Reena *et al*., 2012; Mbiri *et al*., 2017). Total plasma protein is used to assess the changes in renal and hepatic functions, abnormal level of total proteins is related to liver infections or sub-chronic hepatic inflammation (El Kabbaoui *et al*., 2017). Albumin is a protein synthesized in the liver, which when decreased, may be an indication of reduced liver synthetic ability while a high level is associated with dehydration (Donkor *et al*., 2014). Sub-chronic administration of graded doses of ALES did not produce major effects on the serum levels of liver enzymes ALT and AST, bilirubin, and proteins in the experimental animals and their results were comparable to the control group. However, a significant reduction in ALP was observed in groups treated with 500 mg/kg of the extract. Previous researches have shown that reduction in the ALP level may be associated with zinc deficiency, hypothyroidism, vitamin (C and B12) deficiency, and magnesium deficiency (Cho *et al*., 2007; Ray *et al*., 2017). Therefore, the findings of the present study showed decrease in ALP for treatment groups, but only significant at 500

mg/kg thou the significant decrease was not dose dependent, could possibly be attributed to other factors listed above in relation to ALP and could also still suggest ALES interference with mineral nutrients.

Several medicinal plants affect glucose metabolism (Mbiri *et al*., 2017). Studies reported that polyphenols and flavonoids containing substances elicit hypoglycemic effect by inhibiting α amylase and α-glucosidase, increasing glucose uptake by peripheral tissues and stimulating the release of insulin from pancreatic β cells (El Kabbaoui *et al*., 2017). In this study, there was decrease in glucose levels for the rats treated with ALES and this justified the reported traditional uses by Elufioye and Berida, (2018) on the anti-diabetic and cholesterol-lowering effect of *Spondias purpurea*. Muniz-Ramirez *et al*. (2021) reported that the seed extract of *S. purpurea* counteracted hyperglycemic state by stimulating pancreatic islets cell leading to increase insulin secretion. Sub-chronic study on ALES suggests that ALES could also lower glucose level of normoglycemic rats which could be of toxic concern on glucose metabolism.

The kidney plays a significant role in maintaining homeostatic balance by reabsorbing essential substances and excretion of waste products, thus evaluation of urea and creatinine in the blood is used to assess renal function (Donkor *et al*., 2014; Liaqat *et al.,* 2018). There was no observed significant difference in urea and creatinine level in all the groups treated with ALES and the control for sub-chronic administration. Also, serum levels of electrolytes such as chloride and sodium were marginally lower and insignificantly altered compared with their respective controls were. However, a remarkable reduction in potassium was observed in a dose-dependent manner for treated groups as compared to the control for sub-chronic administration of ALES. Yang *et al*. (2019) suggested that severe damage to glomeruli and renal tubules leads to deterioration of renal tubular reabsorption and glomerular filtration mechanisms or high secretion of aldosterone impairs the absorption of ions which can lead to alteration of electrolyte levels or an imbalance. From the sub-chronic toxicity study, the decrease in potassium may indicate renal tubular damage or may indicate a hypokalemic effect.

Hyperlipidemia is considered among the main predisposing factors of atherosclerosis which causes coronary artery diseases. High levels of cholesterol and triglycerides in the blood is related to heart and vascular diseases such as atherosclerosis (Reena *et al*., 2012; Jatsa *et al*., 2018). During the circulation of LDL in the blood, it is deposited within the arterial walls, causing arterial plaques, resulting in atherosclerosis. However, HDL takes cholesterol away from the arteries to the liver for elimination, and therefore an elevation of HDL prevents atherosclerosis and cardiovascular diseases, while increase LDL level is a risk factor of cardiovascular diseases (Jatsa *et al*., 2018). Based on this study, ALES 500 and 1000 mg/kg treatment group produces a significant decrease in triglyceride level compared to the control group. So also, there was an observed insignificant decrease in cholesterol and LDL levels as well as an increase serum levels of HDL compared to their respective control. Suggesting that the extract may have a good effect on lipid metabolism. This result corroborates findings of Muniz-Ramirez *et al*. (2021) who studied the antihyperlipidemic effect of *spondias purpurea* seed on zebra fish model.

The results of histological examination showed no marked alterations in the histo-morphology of the myocardium of the heart

and mucosa of the stomach, which suggested the extract's non-toxic effect on the heart and stomach. However, kidney showed slight tubular necrosis (1000 mg/kg ALES), slight tubular adhesion (500 mg/kg) resulting from delivery of toxic substances to the kidney from systemic circulation and may cause loss of integrity of the renal tubular system. Additionally, the liver also showed slight hepatic necrosis in groups treated with 1000 mg/kg of ALES. Thus, due to the role of the kidney and liver in metabolism, this slight alteration could possibly account for the variations seen in some of the biochemical parameters of this study.

Neurons are electrically excitable cells that conduct and transmit signals all over the body through electrical and chemical signaling. Slight neuronal necrosis observed in group treated with the highest dose of ALES (1,000 mg/kg) may interfere with conduction and transmission of signals across the neuronal cell. Usually, neurons propagate their action potentials by ion movement of which sodium and potassium ions are most commonly involved (Salatino *et al*., 2017).

The alveoli are tiny air sacs in the lungs where the exchange of gases takes place. Slight hyperplasia of inflammatory cells observed in treated group (1000 mg/kg) may interfere with exchange process of gases across the alveoli epithelium into the circulation, though these changes were insignificant in the relative organ weight of the lung.

Uterus plays a key role in reproductive health and functions majorly in pregnancy, fertility and menstrual cycle. Endometrial hyperplasia is a heterogeneous set of pathologic lesions that range from mild, reversible glandular oliferations to direct cancer precursors (Olowofolahan *et al*., 2021). Effect of sub-chronic administration of ALES at 1000 mg/kg showed glandular hyperplasia on uteri, represented by an abundance of dilated glands with large lumens. This could suggest possibly estrogenic properties of ALES usually the consequence of which are hyperplasia of the endometrium. The hyper-stimulatory effects and resulting glandular hyperplasia can in the long run generate more negative effects which may affects the functioning of the uterus.

In conclusion, the results of this study showed that acute oral administration of aqueous leaf extract of *S. purpurea* has relative acute safety, it produced low systemic toxicity following sub-chronic repeated administration, with slight to moderate histomorphological changes observed in the kidneys, liver, brain, lungs and uterus.

Conflict of Interest

The authors declared no conflict of interest

Acknowledgement

The authors appreciate the management of the Department of Pharmacology and Therapeutics, Department of Pharmacognosy and Drug Discovery, Ahmadu Bello University, Zaria-Nigeria for provision of laboratories where the research was conducted, and also Mr. Muazu Mahmud and Ibrahim Kabiru for their technical support in the respective department.

References

Abotsi, W. K., Ainooson, G. K., Gyasi, E. B., & Abotsi, W. K. M. (2011). Acute and sub-acute toxicity studies of the ethanolic extract of the aerial parts of *Hilleria latifolia* (Lam.) H. Walt. (Phytolaccaceae) in rodents. *West African Journal of Pharmacy*, 22(1), 27-35.

Abubakar, A., Nazifi, A. B., Hassan, F. I., Duke, K. A., & Edoh, T. D. (2019). Safety assessment of *Chlorophytum alismifolium* tuber extract (Liliaceae): Acute and sub-acute toxicity studies in Wistar rats. *Journal of Acute Disease*, 8(1), 21 https://www.jadweb.org/text.asp?2019/8/1/21/250374

Adegbola, P. I., Adetutu, A., & Olaniyi, T. D. (2020). Antioxidant activity of *Amaranthus species* from the Amaranthaceae family–A review. *South African Journal of Botany*, 133, 111-117. https://doi.org/10.1016/j.sajb.2020.07.003

Al-Doori, A., Ahmed, D., Kadhom, M., & Yousif, E. (2021). Herbal medicine as an alternative method to treat and prevent COVID-19. *Baghdad Journal of Biochemistry and Applied Biological Sciences*, 2(01), 1-20. https://doi.org/10.47419/bjbabs.v2i01.25

Alfaro, M. A. M. (1984). Medicinal plants used in a totonac community of the sierra norte de puebla: Tuzamapan de gale ana, puebla, Mexico. *Journal of Ethnopharmacology*, 11(2), 203-221. https://doi.org/10.1016/0378-8741(84)90039-4

Allain, C. C., Poon, L. S., Chon, C. S. G., Richmond, W. and Fu, P. C. (1974). Enzymatic determination of total serum cholesterol. *Clinical Chemistry*, 20: 470-475.

Ayéna, A. C. T., Dosseh, K., Idoh, K., Agbonon, A., & Gbeassor, M. (2022). Comparative Physicochemical Screening and Toxicology of Hydroethanol Extracts of the Parts of *Pterocarpus santalinoides* l'Her. ex DC. (Fabaceae) in Wistar Rats. *The Scientific World Journal*, *2022*.

Bernstein, N., Akram, M., Yaniv-Bachrach, Z., & Daniyal, M. (2021). Is it safe to consume traditional medicinal plants during pregnancy? *Phytotherapy Research*, 35(4), 1908-1924. https://doi.org/10.1002/ptr.6935

Bose, S., Datta, R., & Kirlin, W. G. (2021). Toxicity Studies Related to Medicinal Plants. In *Evidence Based Validation of Traditional Medicines* (pp. 621-647) http://dx.doi.org/10.1007/978-981-15-8127-4_30

Brun, JL, Descat, E., Boubli, B., & Dallay, D. (2006). Endometrial hyperplasia. *Journal of Obstetrics and Gynecology and Reproductive Biology*, 35(6): 542-550.

Carbone, M., & Strazzabosco, M. (2020). Introduction to the Physiology, Immunology and Pathology of the Liver and Biliary Tree. *Autoimmune Liver Disease: Management and Clinical Practice*, 3-20. https://doi.org/10.1002/9781119532637.ch1

Cho, Y. E., Lomeda, R. A. R., Ryu, S. H., Sohn, H. Y., Shin, H. I., Beattie, J. H., & Kwun, I. S. (2007). Zinc deficiency negatively affects alkaline phosphatase and the concentration of Ca, Mg and P in rats. *Nutrition Research and Practice*, 1(2), 113119.

Clark, M., & Steger-Hartmann, T. (2018). A big data approach to the concordance of the toxicity of pharmaceuticals in animals and humans. *Regulatory Toxicology and Pharmacology*, 96, 94-105. https://doi.org/10.1016/j.yrtph.2018.04.018

Datta, B. K., Bhar, M. K., Patra, P. H., Majumdar, D., Dey, R. R., Sarkar, S., ... & Chakraborty, A. K. (2012). Effect of environmental exposure of arsenic on cattle and poultry in nadia district, west bengal,

India. *Toxicology International*, 19(1), 59. http://dx.doi.org/10.4103/0971-6580.94511

David, B., Wolfender, J. L., & Dias, D. A. (2015). The pharmaceutical industry and natural products: historical status and new trends. *Phytochemistry Reviews*, 14(2), 299-315. http://minerva-access.unimelb.edu.au/bitstreams/0b9965af-7ac0-5d0c-a2ad-1879efe255b6/download

Doumas, B. T., Watson, W. A., & Biggs, H. G. (1997). Albumin standards and the measurement of serum albumin with bromcresol green. *Clinical Chemistry*, *258*(1), 21-30.

Donkor, K., Okine, L. N., Abotsi, W. K., and Woode, E. (2014). Acute and Chronic Toxicity Studies of aqueous extract of root bark of *Cassia sieberiana* DC in Rodents. *Journal of Applied Pharmaceutical Sciences*, 4(4): 084-089. http://dx.doi.org/10.7324/JAPS.2014.40415

El Kabbaoui, M., Chda, A., El-Akhal, J., Azdad, O., Mejrhit, N., Aarab, L., ... and Tazi, A. (2017). Acute and chronic toxicity studies of the aqueous extract from leaves of *Cistus ladaniferus* L. in mice and rats. *Journal of ethnopharmacology*, 209, 147-156. https://doi.org/10.1016/j.jep.2017.07.029

Elufioye, T.O. and Berida, T.I., 2018. GC-MS analysis and antioxidant activity *of Spondias purpurea* L (Anacardiaceae). *Pharmacognosy Journal*, 10(5). http://dx.doi.org/10.5530/pj.2018.5.159

Friedewald, W. T., Levy, R. I. and Fredickson, D. S. (1972). Estimation of the concentration of low density lipoprotein cholesterol in plasma without the use of preparative ultracentrifuge. *Clinical Chemistry*, 18: 499-502.

Gara, T. Y., Daniel, A. I., Muhammad, F. M., & Ndayako, H. H. (2021). Toxicological studies of aqueous and ethanol leaf extract of *Spondias purpurea* (red plum) in rats. *Clinical Phytoscience*, 7(1), 1-9. https://clinphytoscience.springeropen.com/counter/pdf/10.1186/s40816-021-00331-y.pdf

Harizal, S. N., Mansor, S. M., Hasnan, J., Tharakan, J. K. J., & Abdullah, J. (2010). Acute toxicity study of the standardized aqueous extract of *Mitragyna speciosa* Korth in rodent. *Journal of Ethnopharmacology*, 131(2), 404-409. https://doi.org/10.1016/j.jep.2010.07.013

Heinegård, D., & Tiderström, G. (1973). Determination of serum creatinine by a direct colorimetric method. *Clinical Chemistry*, *43*(3), 305-310.

Jatsa, H. B., Fassi, J. B. K., Kenfack, M. C., Feussom, N. G., Kameni, M. P., Simo, N. D., ... and Tchuente, L. A. T. (2018). Acute and chronic oral toxicity studies of the leaves aqueous extract of *Clerodendrum umbellatum* Poir. on mice. *American Journal of Physiology, Biochemistry and Pharmacology*, 7(2): 75-85.

Jothy, S. L., Zakaria, Z., Chen, Y., Lau, Y. L., Latha, L. Y., & Sasidharan, S. (2011). Acute oral toxicity of aqueousic seed extract of *Cassia fistula* in mice. *Molecules*, 16(6), 5268-5282. https://doi.org/10.3390/molecules16065268

Kifayatullah, M., Mustafa, M. S., Sengupta, P., Sarker, M. M. R., Das, A., & Das, S. K. (2015). Evaluation of the acute

and sub-acute toxicity of the ethanolic extract of *Pericampylus glaucus* (Lam.) Merr. in BALB/c mice. *Journal of Acute Disease*, 4(4), 309-315. https://doi.org/10.1016/j.joad.2015.06.010

Kuissu Mimosette, M., Enow-Orock George, E., Mezui Christophe, N., Ernestine, Z., Benjamin, N., & Siwe Gael, T. (2020). Evaluation of the toxicity of the aqueous stem bark extract of *Enantia chlorantha* on some reproductive and developmental parameters. *Journal of Medicinal Plants*, 8(2): 86-94.

Liaqat, I., Riaz, N., Saleem, Q. U. A., Tahir, H. M., Arshad, M., & Arshad, N. (2018). Toxicological evaluation of essential oils from some plants of Rutaceae family. *Evidence-Based Complementary and Alternative Medicine*, 2018. https://doi.org/10.1155/2018/4394687

Lorke, D. (1983). A new approach to practical acute toxicity testing; *Archives of Toxicology.* 54: pp. 275–287. https://doi.org/10.1007/bf01234480

Luo, Y., Wang, C. Z., Hesse-Fong, J., Lin, J. G., & Yuan, C. S. (2019). Application of Chinese medicine in acute and critical medical conditions. *The American Journal of Chinese Medicine*, 47(06), 1223-1235. https://doi.org/10.1142/s0192415x19500629

Mabeku, L. B. K., Beng, V. P., Kouam, J., Essame, O., & Etoa, F. X. (2007). Toxicological evaluation of ethyl acetate extract of *Cylicodiscus gabunensis* stem bark (Mimosaceae). *Journal of Ethnopharmacology*, 111(3): 598-606. https://doi.org/10.1016/j.jep.2007.01.010

Marisco, G., & Pungartnik, C. (2015). *Spondias purpurea* L.(Anacardiaceae): traditional uses, chemical composition and biological activities. *Scientia Amazonia*, 4(2), 10-18.

Mbiri, J. W., Musila, M. N., Ngai, D. N., Njagi, S. M., Mbinda, W. M., and Ngugi, M. P. (2017). Acute and chronic oral toxicity study of aqueous extract of *Caesalpinia volkensii* (harms). *Journal of Drug Metabolism and Toxicology*, 8(1): 222-229. doi:10.4172/2157-7609.1000222

Mensah, M. L., Komlaga, G., Forkuo, A. D., Firempong, C., Anning, A. K., & Dickson, R. A. (2019). Toxicity and safety implications of herbal medicines used in Africa. *Herbal Medicine*, 63: 1992-0849.

Mitsios, A., Chrysanthopoulou, A., Arampatzioglou, A., Angelidou, I., Vidali, V., Ritis, K., ... & Stakos, D. (2020). Ticagrelor exerts immune-modulatory effect by attenuating neutrophil extracellular traps. *International Journal of Molecular Sciences*, *21*(10), 3625. https://doi.org/10.3390/ijms21103625

Mokua, S. K., Mbaria, J. M., Maitho, T. E., & Moriasi, G. A. (2021). Ethnobotanical documentation, phytochemical screening, and cytotoxicity evaluation of medicinal plants used to manage snakebite envenomation in Mwingi West subcounty, Kenya. *Evidence-Based Complementary and Alternative Medicine*, 2021.

Muñiz-Ramirez, A., Garcia-Campoy, A. H., Pérez Gutiérrez, R. M., Garcia Báez, E. V., & Mota Flores, J. M. (2021). Evaluation of the antidiabetic and antihyperlipidemic activity of *spondias purpurea* seeds in a diabetic zebrafish model. *Plants*, 10(7): 1417.

Nandagoapalan, V., Doss, A., & Marimuthu, C. (2016). Phytochemical analysis of some traditional medicinal plants. *Bioscience Discovery*, 7(1), 17-20.

https://www.researchgate.net/publication/310611077_Phytochemical_analysis_of_some_Traditional_medicinal_plants

OECD (2018), Test No. 408: Repeated Dose 90-day Oral Toxicity Study in Rodents. OECD Guidelines for the Testing of Chemicals. https://doi.org/10.1787/20745788

Okpuzor, J., Adebesin, O., Ogbunugafor, H., & Amadi, I. (2021). The potential of medicinal plants in sickle cell disease control: A review. *International Journal of Biomedical and Health Sciences*, 4(2). https://www.researchgate.net/publication/228479833_The_potential_of_medicinal_plants_in_sickle_cell_disease_control_A_review

Olowofolahan, A. O., Oyebode, O. T., & Olorunsogo, O. O. (2021). Methyl palmitate reversed estradiol benzoate-induced endometrial hyperplasia in female rats. *Toxicology Mechanisms and Methods*, 31(1): 43-52

Oluwaiye, J. O., Kwanashie, H. O., & Anafi, S. B. (2020). Preliminary Comparative Phytochemical, Elemental and Acute Toxicity Analyses of Selected Conventional and Herbal Medicines. *The FASEB Journal*, 34(S1), 1-1 https://doi.org/10.1096/fasebj.2020.34.s1.07566

Ozioma, E. O. J., & Chinwe, O. A. N. (2019). Herbal medicines in African traditional medicine. *Herbal Medicine*, 10, 191-214.

Ramaiah, S. K. (2007). A toxicologist guide to the diagnostic interpretation of hepatic biochemical parameters. *Food and Chemical Toxicology*, 45(9), 1551-1557. https://doi.org/10.1016/j.fct.2007.06.007

Ray, C. S., Singh, B., Jena, I., Behera, S., & Ray, S. (2017). Low alkaline phosphatase (ALP) in adult population an indicator of zinc (Zn) and magnesium (Mg) deficiency. *Current Research in Nutrition and Food Science Journal*, 5(3), 347-352.

Reena, G., Sanjiv, D., and Bhupinder, K. (2012). Chronic toxicity study of aqueous extract of *Clerodendrum phlomidis* leaves. *International Journal of Drug Development and Research*, 4(3): 197-207.

Reena, G., Sanjiv, D., and Bhupinder, K. (2012). Chronic toxicity study of aqueous extract of *Clerodendrum phlomidis* leaves. *International Journal of Drug Development and Research*, 4(3): 197-207. https://www.researchgate.net/publication/287454799

Reitman, S., & Frankel, S. (1957). A colorimetric method for the determination of serum glutamic oxalacetic and glutamic pyruvic transaminases. *American Journal of Clinical Pathology*, *28*(1), 56-63.

Roland, K. E. B., Eugène, A. S., F&elix, G., Maximin, S., & Latifou, L. (2022). Toxicological assessment of ethanolic extracts of *Annona senegalensis* and *Trichilia prieureana* in the treatment of type 2 diabetes in Benin. *Journal of Physiology and Pathophysiology*, *13*(2), 27-35.

Rolls, G. (2011). Microtomy and paraffin section preparation. *see http://www. leicabiosystems. com/pathologyleaders/microtomy-and-paraffin-section-preparation*.

Saganuwan, S. A. (2017). Toxicity studies of drugs and chemicals in animals: an overview. *Bulgarian Journal of Veterinary Medicine*, 20(4): 10.15547/bjvm.983

Salatino, J. W., Ludwig, K. A., Kozai, T. D., & Purcell, E. K. (2017). Glial responses to

implanted electrodes in the brain. *Nature biomedical engineering*, *1*(11), 862-877.

Siddharthan, T., Ramaiya, K., Yonga, G., Mutungi, G. N., Rabin, T. L., List, J. M., ... & Schwartz, J. I. (2015). Noncommunicable diseases in East Africa: assessing the gaps in care and identifying opportunities for improvement. *Health Affairs*, 34(9): 1506-1513. https://doi.org/10.1377/hlthaff.2015.0382

Süntar, I. (2020). Importance of ethnopharmacological studies in drug discovery: role of medicinal plants. *Phytochemistry Reviews*, 19(5), 1199-1209. https://link.springer.com/article/10.1007/s11101-019-09629-9

Traesel, G. K.,de Souza, J. C., de Barros, A. L., Souza, M. A., Schmitz, W. O., Muzzi, R. M., … and Arena, A. C. (2014). Acute and subacute (28 days) oral toxicity assessment of the oil extracted from *Acrocomia aculeate* pulp in rats. *Food and Chemical Toxicology*, 74, 320-325. https://doi.org/10.1016/j.fct.2014.10.026

Vaghasiya, Y. K., Shukla, V. J., & Chanda, S. V. (2011). Acute oral toxicity study of Pluchea arguta boiss extract in mice. *Journal of Pharmacology and Toxicology*, 6(2), 113-23. https://dx.doi.org/10.3923/jpt.2011.113.123

Wang, L., Li, Z., Li, L., Li, Y., Yu, M., Zhou, Y., Lv, X., Arai, H., Xu, Y., 2014. Acute and chronic oral toxicity profiles of the aqueous extract of *Cortex dictamni* in mice and rats. *Journal of Ethnopharmacology* 158, 207-215. https://doi.org/10.1016/j.jep.2014.10.027

Yamssi, C., Payne, V. K., Noumedem Anangmo, C. N., Tateng Ngouateu, A., Megwi, L., & Kuiate, J. R. (2020). Acute Toxicity of *Pentaclethra macrophylla* and *Psidium guajava* Use as Antiprotozoan Medicinal Plants. *Journal of Drug Discovery, Development and Delivery*, 6(1), 1037.

Yuet Ping, K., Darah, I., Chen, Y., Sreeramanan, S., and Sasidharan, S. (2013). Acute and subchronic toxicity study of *Euphorbia hirta* L. methanol extract in rats. BioMed Research International, 2013. Doi.org/10.1155/2013/182064.

Wanjiru, J. N., Maitho, T. E., Mbaria, J. M., & Moriasi, G. A. (2022). Subacute toxicity effects of the aqueous shoot extract of *Yushania alpina* (K. Schum.) WC Lin in Sprague Dawley rats: an appraisal of its safety in Ethnomedicinal usage. *Journal of Toxicology*, 2022.

World Health Organization. (2013). *WHO traditional medicine strategy: 2014-2023*. World Health Organization.