Evaluation of the effect of antibiotics, anti-inflammatory agent, and monoclonal antibody on the gastrointestinal tract in a rat model of acetic acid-induced ulcerative colitis

Olusoji Adebusoye Oyesola*[1], Oluwatosin Soyinka[2], Olaniyi Soetan[1], Eunice Oluwabunmi Ojo-Adebayo[1], Victoria Biola Edema[1], Oluwaseye Olayemi[1]

[1]Department of Physiology, Olabisi Onabanjo University, Sagamu Campus, Ogun State.
[2]Department of Chemical Pathology, Olabisi Onabanjo University, Sagamu Campus, Ogun State.

Submitted: 1st Oct., 2024; Accepted: 7th Oct., 2024; Published online: 31st October, 2024
DOI: https://doi.org/10.54117/jcbr.v4i5.5
**Corresponding Author: Olusoji Oyesola; olusoji.oyesola@oouagoiwoye.edu.ng*

Abstract

Ulcerative colitis (UC) is a chronic inflammatory bowel disease characterized by gut pathology and impaired gut function. This study aimed to evaluate the efficacy of antibiotic, anti-inflammatory, and monoclonal antibody therapies on gut pathology in a rat model of acetic acid-induced UC.

Fifty Adult Male Sprague-Dawley rats were divided into five groups of ten rats each, the animals were allowed to acclimatize for a period of 2 weeks. The induction of the ulcerative colitis was done according to the method described by Al-Rejaie et al., (2013), after 24 hours fast, 2 ml of 4% acetic acid solution was administered transrectally using a (2.7 mm) soft pediatric catheter. After acetic acid administration, rats were holed horizontally for 2 min to prevent acetic acid leakage. Manifestation of Ulcerative Colitis was observed in the rats after 6 days of induction and treatment was carried out for a period of 42 days. Group A was the normal control. UC was induced with 2 ml of 4% acetic acid solution transrectally using soft pediatric catheter in Group B while, Group C and D received 40 mg/kg of Ciproflaxin and 100 mg/kg of Prednisolone respectively every 72 hours for forty-two days orally, and Group E received 5 mg/kg of infliximab for 2 weeks Intraperitoneally. At the end of 42 days, Total acidity, Gastric mucus concentration and pH were determined using standard method; MDA- Lipid Peroxidation was also determined in the stomach, pancreas, small and large intestine. The Histoarchitecture of the stomach, small and large intestine were studied.

The UC-induced group showed significant changes in gut physiology and pathology, including decreased pH, increased total acidity, reduced mucin content, elevated

malondialdehyde (MDA) levels, and increased clinical symptoms. In contrast, all treatment groups showed significant improvements in gut physiology, contributing positively to ameliorating the symptoms and pathological features of ulcerative colitis with varying efficacy. Histological analysis revealed significant pathological changes in the UC-induced group, including thickened muscularis, degenerated mucosa, and compromised submucosa, which were improved in the anti-inflammatory-treated and monoclonal antibody-treated groups.

The study effectively highlights the significant impacts of antibiotic, anti-inflammatory agent and monoclonal antibody in improving in gut physiology on various parameters associated with UC potentially through the regulation of gastrointestinal secretions, reduction of pro-inflammatory cytokines, which contribute to UC severity, inhibition of oxidative stress, which can damage the gut barrier and exacerbate UC, increase in mucin content, which can protect the gut barrier and reduce UC severity, and modulation of the gut microbiome, which can influence UC severity. The findings indicate that while all the three interventions contribute positively to ameliorating the symptoms and pathological features of UC, their overall efficacy vary. This study provides insights into the efficacy of the different therapies on gut pathology in UC and may inform the development of novel treatments for this debilitating disease.

Introduction

Ulcerative colitis (UC) is a chronic inflammatory bowel disease (IBD) characterized by mucosal inflammation, ulceration, and dysfunction of the colonic epithelial barrier (Lynch and Hsu, 2023). The exact etiology of UC remains unclear, but it is believed to result from an aberrant immune response, environmental triggers and genetic predisposition (Ungaro *et al.,* 2019; Roberts *et al.,* 2019). The current treatment paradigm for UC includes antibiotics, anti-inflammatory agents, and monoclonal antibodies, which often yield variable responses and are associated with significant side effects (Kayal and Shah, 2019; Aslam *et al.,* 2022).

Acetic acid-induced colitis in rats is a well-established model for studying UC, recapitulating key features of human disease, including mucosal inflammation, ulceration, and epithelial dysfunction. This model provides a valuable platform for evaluating the efficacy of various therapeutic interventions and understanding the underlying mechanisms of UC (Owosu *et al.,* 2020*;* Subramanian *et al.,* 2022).

Recent studies have highlighted the critical role of the gut microbiome, epithelial barrier function, and immune regulation in the pathogenesis of UC (Porter and Ho, 2020; Swirkosz *et al.,* 2023; Schreiber *et al.,* 2024). Antibiotics, anti-inflammatory agents, and monoclonal antibodies have shown promise in modulating these pathways, but their comparative efficacy in mitigating gut pathology in UC is not well understood. This study aims to evaluate the comparative efficacy of antibiotic, anti-inflammatory, and monoclonal antibody therapies on gut pathology in an acetic acid-induced UC rat model.

Methodology

Animal Grouping

Fifty adult male Sprague-Dawley rats were used for this study and were divided into five groups of ten rats each.

Table 1: Animal grouping

Group	Treatment
A: Normal control	Normal saline (0.9% w/v NaCl) P.O
B: Ulcerative colitis group	2 ml/kg 4% acetic acid solution transrectal
C: Antibiotics group	2 ml/kg 4% acetic acid solution transrectal and 40mg/kg of ciprofloxacin (P.O)
D: Anti-inflammatory agent group	2 ml/kg 4% acetic acid solution transrectal and 100mg/kg of prednisolone (P.O)
E: Monoclonal antibody group	2 ml/kg 4% acetic acid solution transrectal and 5 mg/kg of infliximab (i.p)

P.O: per oral **i.p: intraperitoneal**

The National Research Council's guidelines for the care and use of laboratory animals were followed in all animal studies and methodology. Ethical approval was obtained from Olabisi Onabanjo University Teaching Hospital Human Research Ethics Committee (OOUTH-HREC), with the number OOUTH/HREC/746/2023AP.

Induction of ulcerative colitis

The animals were anesthetized using 1.75 mL ketamine (1000 mg/mL) and 0.25 mL Xylazine (1000 mg/mL) intra- peritoneal prior to ulcerative colitis induction. The induction

of the ulcerative colitis was done according to the method described by Al-Rejaie et al., (2013), after 24 hours fast, 2 ml of 4% acetic acid solution was administered transrectally using a (2.7 mm) soft pediatric catheter. After acetic acid administration, rats were holed horizontally for 2 min to prevent acetic acid leakage. Control animals underwent the same procedure using equal volume of normal saline instead of acetic acid solution. After the manifestation of ulcerative colitis on the 6th day, treatment was carried for a period of 42 days.

Administration of antibiotics, anti-inflammatory agent and monoclonal antibody

The antibiotics, anti-inflammatory agent and monoclonal antibody used in this study were ciprofloxacin, prednisolone and infliximab respectively. Ciproflaxin(40 mg/kg) was administered every 72 hours for forty-two days orally (Collins *et al.,* 1989), 100mg/kg of prednisolone was also administered every 72 hours for forty-two days orally (Witaicenis *et al.,* 2012), and 5 mg/kg of infliximab was administered bi-weekly for 6 weeks intra-peritoneal (Triantafyllidis *et al.,* 2005).

Hyperemia, adhesions, megacolon and ulcerations assessment protocol

Every day, the animals were examined for any obvious abnormalities such as loose feces, diarrhea, or bloody stools. Every week after ulcerative colitis induction, the weight of each animal was recorded to monitor for weight loss. A numerical score based on these observations was provided (Table 2).

Table 2 hyperemia, adhesions, megacolon and ulcerations assessment protocol

Feature	0	1	2	3
Hyperemia	None	Focal	Focal and thickening of bowel wall	Extensive thickening of bowel wall
Adhesions	None	Mild	Moderate	Extensive
Megacolon	None	Mild	Moderate	Toxic megacolon
Ulcerations	None	Mild ulceration on one side < 1 cm	Moderate ulceration > 1 cm	Severe damage extending > 2 cm

Determination of ph, total acidity and gastric mucus concentration

Measurements of the gastric juice's pH, total acidity, and free acidity were done in accordance with the method outlined by Zakaria *et al.,* (2011). The abdomen of each rat was opened under a mild anesthesia without damaging any blood supply. Gastric pH was measured using pH meter and recorded. The gastro-esophageal and gastro-duodenal junctions were secured before the stomach was isolated. One milliliter (1 ml) of distilled water was introduced into the stomach and the organ was carefully shaken. Gastric juice was collected and centrifuged at 3000 rpm for 10 minutes. The supernatant was taken and diluted 10 times. Two to three drops of phenolphthalein were added to the solution. Titration was done using 0.01 M solutions of NaOH until the color of the test solution changed to light pink, indicating a pH of 7. The volume of NaOH was used to determine the hydrogen ion concentration. Acidity was determined using the equation described by Blood, as follows:

$$\frac{volume\ of\ NaOH \times\ normality\ of\ NaOH \times 100}{0.1} mEq/ltr$$

The technique outlined by Corne et al., (1974) was utilized to ascertain gastric mucus concentration. The excised stomach was soaked for 2hours in 0.1% Alcian blue dissolved in a buffer solution containing 0.1M sucrose and 0.05M Sodium acetate (pH adjusted to 5.8 with hydrochloric acid). The dye formed complexes with mucus after washing two times in 0.25M sucrose at 15 and 45 minutes. The mucus was eluted by immersion in 10 mL aliquots of 0.5M $MgCl_2$ for 2 hours. The resulting blue solution was shaken with equal volumes of diethyl ether and centrifuged at 3000 rpm for 10 minutes. The optical density of the aqueous phase was measured at 580 nm using a spectrophotometer. Values of the absorbance measured in the different treatment groups was used to determine the corresponding concentration of alcian blue which formed complexes with mucin on the wall of the glandular portion of the stomach. Finally, the amount of mucin per gram of the net glandular tissue was calculated with a formula as shown below;

$$\text{Mucin content}(\mu g\ \text{Alcian blue/g wet tissue}) = \frac{\text{Alcian blue}\ (\mu g)}{\text{Weight of glandular tissue}\ (g)}$$

Determination of malondialehyde activity (lipid peroxidation)

The malondialdehyde activity of the gut was estimated using the method of Stocks and Dormandy (1971). One milliliter (1 ml) of serum or tissue homogenate was combined with 2 ml of TCA-TBA-HCL and mixed thoroughly. The solution was heated for 15 minutes in a boiling water bath. After cooling, the flourescent precipitate was removed by centrifugation at 1000g for 10 mins. The absorbance of the sample was determined at 535 nm against a blank that contains all the reagents minus the sample. The malondialdehyde concentration of the sample was calculated using an extinction coefficeient of 1.56×10^{-5} M^{-1} Cm^{-1}.

Calculation of lipid peroxidation

$$\text{MDA(nmol/ml)} = \boldsymbol{OD} \sum \times \frac{\boldsymbol{V}}{\boldsymbol{v}}$$

OD = Absorbance (optical density) of sample

$\sum$ = Molar extinction coefficient

V = Total volume of the reacting sample

v = Volume of the sample

Histological analysis

The organs were carefully removed, and then the fat was removed. After weighing, they were fixed in 10% formal saline right away. The tissues were fixed, placed in progressively higher alcohol grades, and finally cleansed in xylene. After embedding them in paraffin, 5µm serial slices were produced. Hematoxylin and eosin were used to stain the sections. A numerical score representing the anomalies in the colon was calculated by evaluating the microscopic changes based on the standards outlined in Table 3. From 0 (normal) to 3 (severe inflammatory response), the histological grades were assigned.

Table 3

Feature	0	1	2	3
Abnormalities of mucosal architecture	None (Normal)	Mild or focal, not exceeding lamina propria	Moderate, not exceeding the submucosa	Severe & diffuse, exceeding the submucosa
Crypt abnormalities	None	Mild atrophy	Moderate atrophy Branched crypts	Severe atrophy, branched crypts, cryptitis, crypt abscess
Inflammatory	Normal	Scattered cells	Moderate or	Massive

cell infiltration			confluent cells	infiltration of cells
Vascular dilatation	Normal blood vessels	Mild dilatation (localized)	Moderate dilatation of several blood vessels	Severe generalized dilatation of blood vessels
Edema	None	Low level limited to villi	In the submucosa	All over the section
Mast cells	Normal scattered cells	Three cells clustered in submucosa	Clusters of > 3 cells in the submucosa	Clusters in submucosa and serosa

Statistical analysis

All the values are expressed as mean ± standard error of mean (SEM). Analysis of data was done using Graph Pad Prism version 5 for Windows. Differences between groups were analyzed by one-way ANOVA followed by Bonferroni *post-hoc* test. Differences were considered significant at $P < 0.05$.

Result and discussion

Table 1: Effect of antibiotic, anti-inflammatory agent and monoclonal antibody on pH in acetic acid induced ulcerative colitis in male rat's model.

Group	pH		
	Stomach	Small intestine	Large intestine
A	4.60±0.24	4.00±0.00	4.25±0.48
B	2.28±0.56[a]	2.06±0.44[a]	2.40±0.40[a]
C	2.50±0.29[a]	3.50±0.29	4.50±0.29[b]
D	4.20±0.58[b]	5.20±0.58[b]	6.20±0.58[ab]
E	4.20±0.58[b]	5.20±0.58[b]	6.20±0.58[ab]

Each value is an expression of mean ± SEM. (P <0.05)

a - Values were significant when compared to group A, b-Values were significant when compared to group B

Table 2: Effect of antibiotic, anti-inflammatory agent and monoclonal antibody on total acidity in acetic acid induced ulcerative colitis in male rat's model.

Group	Total acidity		
	Stomach	Small intestine	Large intestine
A	175.20±11.75	197.65±27.46	142.55±6.20
B	513.20±32.13[a]	415.40±108.89[a]	224.20±28.76
C	158.80±24.75[b]	204.40±48.01[b]	130.60±25.38
D	213.60±37.08[b]	219.20±48.47[b]	136.00±10.83
E	143.80±8.35[b]	164.00±15.48[b]	118.20±9.68

Each value is an expression of mean ± SEM. (P <0.05)

a - Values were significant when compared to group A, b-Values were significant when compared to group B

Table 3: Effect of antibiotic, anti-inflammatory agent and monoclonal antibody on mucin content in acetic acid induced ulcerative colitis in male rat's model.

Group	Mucin content		
	Stomach	Small intestine	Large intestine
A	130.00±5.84	211.20±23.51	160.40±2.94
B	70.60±7.73[a]	72.80±7.21[a]	75.40±11.25[a]
C	109.60±5.48[b]	116.60±5.48[ab]	123.60±5.48[ab]
D	88.80±8.56[a]	95.80±8.65[a]	102.80±8.56[a]
E	143.00±6.15[b]	150.00±6.15[b]	157.00±6.15[ab]

Each value is an expression of mean ± SEM. (P <0.05)

a - Values were significant when compared to group A, b-Values were significant when compared to group B,

Table 4: Effect of antibiotic, anti-inflammatory agent and monoclonal antibody on MDA in acetic acid induced ulcerative colitis in male rat's model.

Group	MDA			
	Stomach	Small Intestine	Large Intestine	Pancreas
A	0.03±0.00	0.04±0.01	0.07±0.01	0.06±0.03
B	0.10±0.03[a]	0.12±0.03[a]	0.15±0.05[a]	0.15±0.09[a]
C	0.06±0.02	0.05±0.02[b]	0.07±0.01[b]	0.13±0.07
D	0.04±0.02[b]	0.03±0.02[b]	0.04±0.04[b]	0.09±0.06[b]
E	0.03±0.00[b]	0.04±0.01[b]	0.05±0.00[b]	0.09±0.04[b]

Each value is an expression of mean ± SEM. (P <0.05)

a - Values were significant when compared to group A, b-Values were significant when compared to group B,

Table 5: Effect of antibiotic, anti-inflammatory agent and monoclonal antibody on Ulceration, Hyperemia, Adhesion and Megacolon in acetic acid induced ulcerative colitis in male rat's model.

Group	Ulceration	Hyperemia	Adhesion	Megacolon
A	0.00±0.00	0.00±0.00	0.00±0.00	1.00±0.63
B	5.00±0.00[a]	2.80±0.20[a]	2.80±0.20[a]	2.20±0.49[a]
C	4.00±0.32[a]	1.60±0.24[ab]	1.60±0.40[ab]	1.80±0.20
D	3.20±0.37[ab]	1.00±0.32[b]	1.40±0.24[ab]	0.60±0.24[b]
E	1.60±0.24[ab]	0.60±0.24[b]	1.00±0.32[b]	0.20±0.20[b]

Each value is an expression of mean ± SEM. (P <0.05)

a - Values were significant when compared to group A, b-Values were significant when compared to group B,

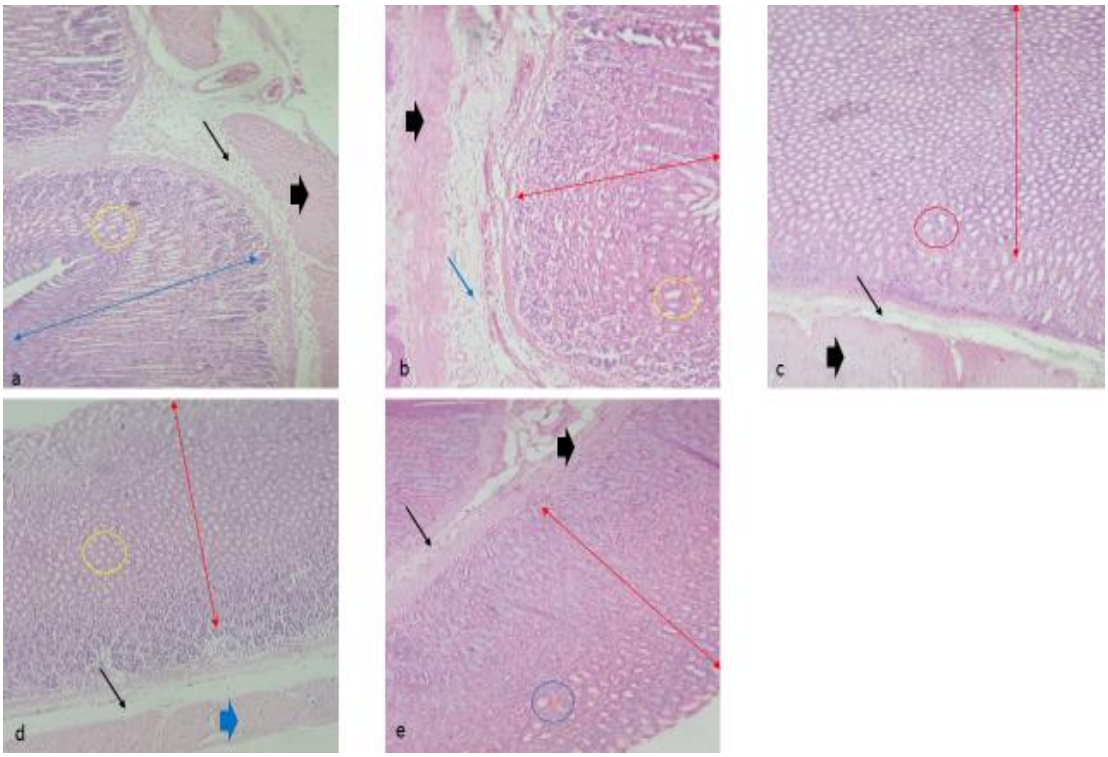

Plate 1. Therapeutic effect of antibiotics (ciprofloxacin hydrochloride), anti-inflammatory agent (prednisolone) and monoclonal antibody (infliximab) on the induced pathological changes in the histoarchitecture of the stomach in adult male Sprague Dawley rats H/E x 200. mucosa region (blue double head arrow), gastric glands (yellow circle), submucosa (black thin arrow) and muscularis layer (black thick arrow).

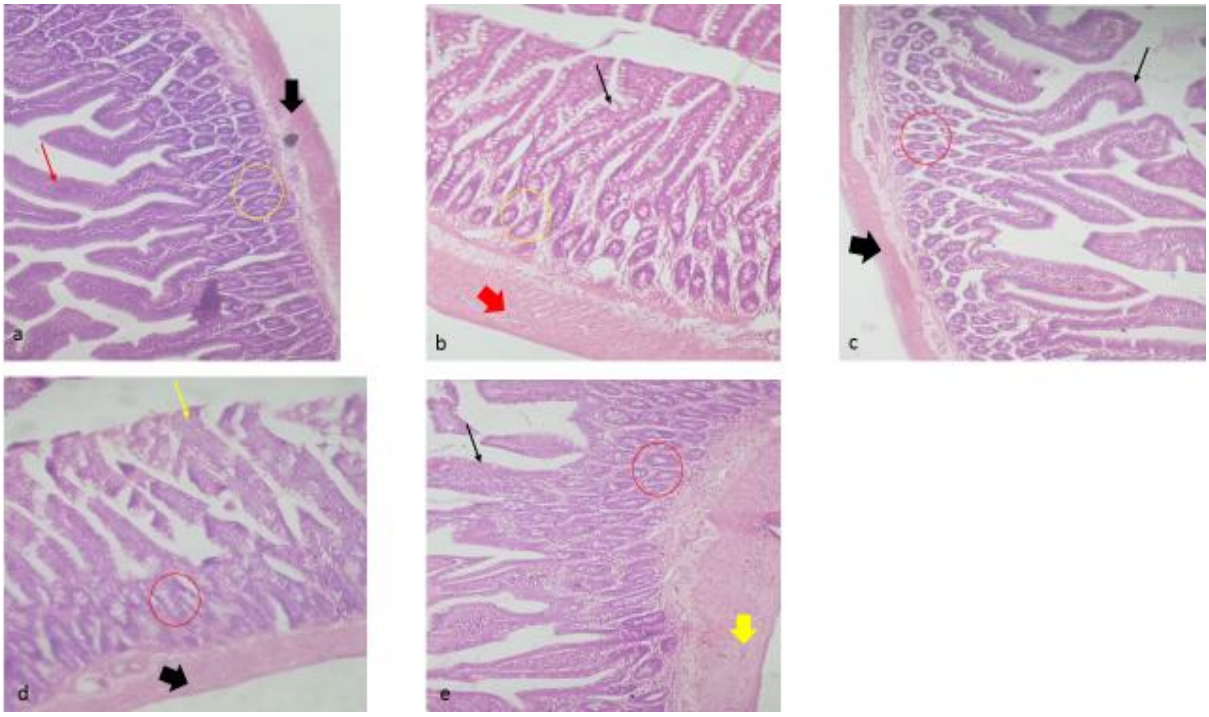

Plate 2. Therapeutic effect of antibiotics (ciprofloxacin hydrochloride), anti-inflammatory agent (prednisolone) and monoclonal antibody (infliximab) on the induced pathological changes in the histoarchitecture of the small intestine in adult male Sprague Dawley rats H/E x 200. villi with goblet cells(red thin arrow), muscularis mucosal(black thick arrow) and brunners glands (yellow circle).

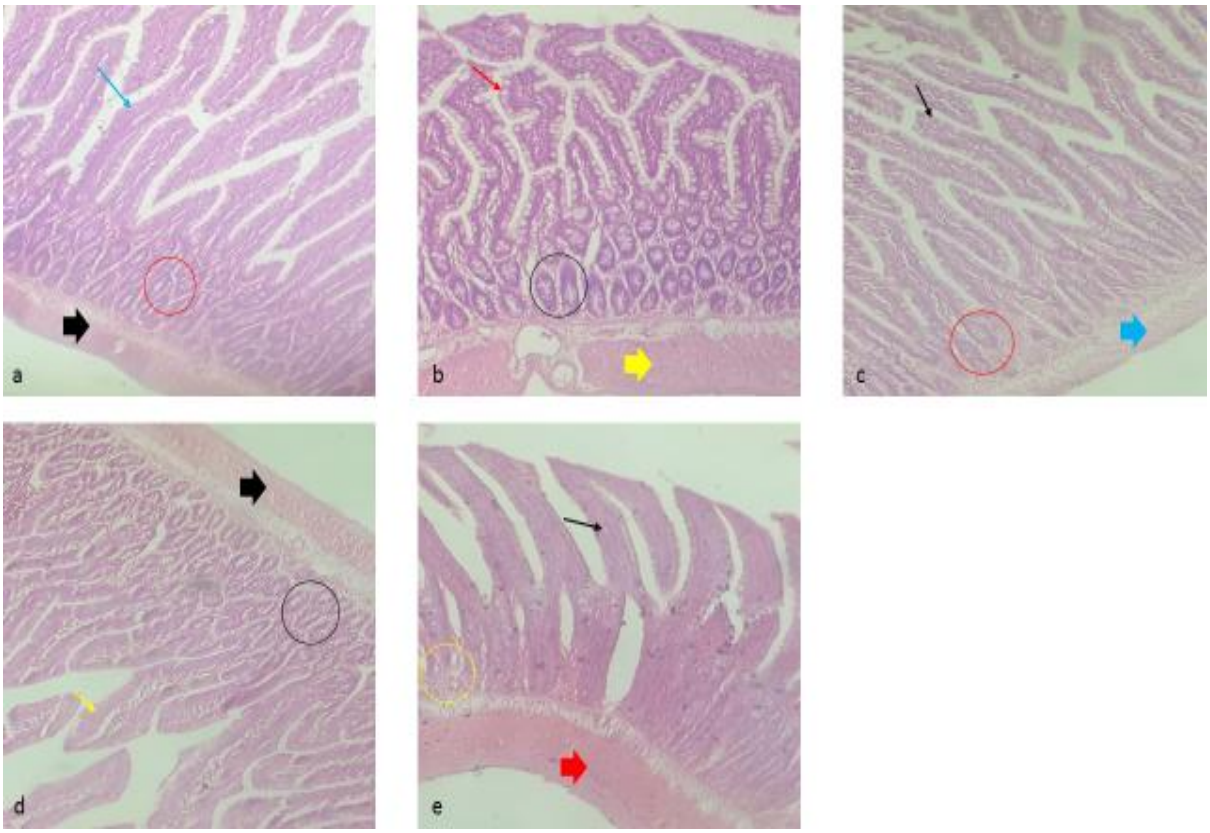

Plate 3. Therapeutic effect of antibiotics (ciprofloxacin hydrochloride), anti-inflammatory agent (prednisolone) and monoclonal antibody (infliximab) on the induced pathological changes in the histoarchitecture of the large intestine in adult male Sprague Dawley rats H/E x 200.

Discussion

The results from the tables above demonstrated significant changes in gut physiology and pathology in acetic acid-induced ulcerative colitis (UC) in Sprague Dawley rats.

The significant decrease in pH level in the untreated UC-induced group (B) (table 1) suggests an increase in acidity causing decreased mucin content as observed in (table 2 and 3), which may exacerbate UC and compromise the gut barrier leading to compromised protective function of the mucus layer, increasing susceptibility to damage and pathogen infiltration. Previous studies showed that UC is associated with increased acidity and mucin depletion in the gut, weakening the mucus barrier, triggering an immune response, mucosal inflammation and ulceration (Dorofeyev *et al.,* 2013; Hauptmann *et al.,* 1998; Nemoto *et al.,* 2012; Niv *et al.,* 2016).

The increase observed in pH and mucin content in the antibiotic group (C), anti-inflammatory-treated group (D) and monoclonal antibody-treated group (E) when compared with group (B) may indicate a protective effect in reducing gut acidity (table 1, 2 and 3 respectively), potentially through increase mucin secretion, acid neutralization, reduction of pro-inflammatory cytokines and oxidative stress (Dinarello *et al.,* 2010; Ahmad *et al.,* 2018).

Notable differences in therapeutic efficacy were observed across all treatment groups. Our findings indicated that monoclonal antibodies, followed by anti-inflammatory agents, demonstrated the most significant therapeutic effect in regulating gut pH, acidity, and mucus content when compared with antibiotics. This therapeutic effect may be due to the fact that antibiotics can also disrupt the gut microbiota balance affecting the balance of different bacterial species that play a role in gut secretions like mucus production and the secretion of substances that help maintain the gut barrier, altering pH, acidity, and mucin production. While effective against harmful bacteria, antibiotics also inhibit beneficial bacteria, potentially exacerbating gastrointestinal issues (Shi *et al.,* 2023; Yang *et al.,* 2024). On the other hand, anti-inflammatory agents indirectly regulate gut secretions by alleviating gastrointestinal inflammation, maintaining optimal mucin production, pH balance, and acidity levels whereas monoclonal antibodies on the selectively target molecules or cells driving gut inflammation and immune responses, effectively regulating immune responses and inflammation (Castelli *et al.,* 2019; Cristofori *et al.,* 2021; Iwai *et al.,* 2010; Marczynski *et al.,* 2021).

According to the result of this study, there was an increase in MDA levels in the UC-induced group indicating a state of chronic oxidative stress, which may contribute to perpetuation of inflammation and mucosal injury. Antibiotics, anti-inflammatory agent and monoclonal antibody significantly reduced MDA levels in the gut mucosa of UC rat model compared to the untreated group suggesting a potential therapeutic benefit, possibly through the reduction of pro-inflammatory cytokines and oxidative stress (Dinarello *et al.,* 2010; Matera *et al.,* 2016). The reduction in MDA levels was most pronounced in the anti-inflammatory agent-treated group, followed by the monoclonal antibody-treated group and the antibiotics-treated group. The reduction in MDA levels may be attributed to the drugs possible mechanisms of action in the gut; antibiotics target gut microbiota, modulate the

composition of the microbiome, reducing bacterial-induced oxidative stress and lipid peroxidation (Shandilya *et al.,* 2021; Airola *et al.,* 2023), anti-inflammatory agents suppress inflammation, thereby mitigating oxidative stress and the subsequent generation of MDA (Kovacic & Somanathan, 2014), while monoclonal Antibodies target specific inflammatory pathways and disrupt the cascade of events leading to lipid peroxidation and MDA formation (Sakuraba *et al.,* 2022).

Antibiotics, anti-inflammatory agent and monoclonal antibody significantly reduced ulceration, hyperemia, adhesion, and megacolon when compared with UC-induced group with maximum therapeutic effect observed in monoclonal antibody followed by anti-inflammatory agent and lastly antibiotics. Antibiotic therapy may restore microbial homeostasis and promote mucosal healing, modulating the gut microbiota and reducing bacterial-induced inflammation thereby alleviating mucosal damage and promoting healing (Ianiro *et al.,* 2016; Mukherjee *et al.,* 2018). It suppresses pathogenic bacteria and the enhancement of beneficial microbial populations, leading to a reduction in inflammatory responses and tissue injury, thus dampening the excessive blood flow and engorgement of vessels seen in inflamed mucosa. Anti-inflammatory agents quell the inflammatory cascade and preserving mucosal integrity (Zhang, 2007; Al-Qahtani *et al.,* 2024). These agents not only alleviate ulceration but also mitigate hyperemia by suppressing the release of pro-inflammatory mediators and inhibiting immune cell infiltration into the gut mucosa. By dampening the inflammatory milieu, anti-inflammatory agents help prevent the formation of adhesions and reduce the risk of megacolon development, thereby improving overall disease outcomes. Monoclonal antibodies specifically block key inflammatory pathways (Lyly *et al.,* 2022); target cytokines involved in the pathogenesis of ulcerative colitis, thereby reducing ulceration, hyperemia, and associated complications. By disrupting the inflammatory signaling cascades responsible for tissue damage, monoclonal antibodies not only alleviate existing gastrointestinal pathologies but also prevent the progression of adhesions and megacolon formation in patients with UC (Kotsovilis and Andreakos, 2014; Zhou *et al.,* 2018).

Regarding the gut histoarchitecture, UC-induced and untreated group showed a significant pathological changes, including thickened muscularis, degenerated mucosa with dilated gastric glands, and a compromised submucosa in the stomach

demonstrating the deleterious effects of acetic acid on gastric tissue integrity (Ungaro *et al.,* 2019). Also, there was a significant villus degeneration, increased goblet cells, thickened muscularis, and altered Brunner's glands, reflecting severe inflammatory damage in the small intestine (Sandborn *et al.,* 2021). Furthermore, an extensive pathological change, including increased and dilated glands of Lieberkuhn, thickened muscularis, and increased goblet cells on the villi, indicating severe inflammatory insult in the large intestine observed.

Different degrees of normalization were observed in the gut architecture on the groups treated with antibiotics, anti-inflammatory agent and monoclonal antibody respectively. Antibiotics treated group showed its efficacy in restoring the integrity of the mucosa, submucosa, and muscularis layers likely due to its ability in eliminating pathological microbes in the gut (Conte *et al.,* 2006; Chen *et al.,* 2019). Similarly, treatment with anti-inflammatory agent showed a reduction in mucosal distortion and an improvement in the submucosa and muscularis, albeit with some residual abnormalities. A study by Hale *et al.,* (2005) showed that anti-inflammatory agents disrupted the epithelial barrier by enhancing intestinal epithelial apoptosis, thus facilitating adhesion and invasion of intestinal bacteria into mucosal tissues. This observation was supported by reports from Sydora *et al.,* (2005) and Lönnroth *et al.,* (2008). Monoclonal antibody also resulted in decreased pathological changes, although some mild distortions in the mucosa and submucosa persisted. A study by Arijs *et al.,* (2018) showed that monoclonal antibody induced histological healing in over 50% of patients with endoscopic healing, with a maximum effect at week 52. It also restored, although incompletely, the colonic expression of many immune-related genes in UC patients who achieved endoscopic healing at week 52. However, persistent histological and genetic dysregulations remained even in healing patients, suggesting that maintenance therapy may be needed to control intestinal inflammation.

In the small intestine, antibiotics treated group facilitated the regeneration of villi, normalization of goblet cells, and restoration of the muscularis mucosa and Brunner's glands. Anti-inflammatory agent group also improved villus morphology and muscularis structure but showed slight goblet cell loss (Gomollon *et al.,* 2020) while Infliximab treated group resulted in regenerated glands, restored villi with goblet cells, and a normalized muscularis mucosa, underscoring

its effectiveness in ameliorating inflammatory damage (Ben and Chowers, 2014).

Concerning the effect of ulcerative colitis in the large intestine, antibiotics treated group restored normal distribution of the glands of Lieberkuhn, goblet cells, and muscularis layer, demonstrating significance at $p< 0.05$ therapeutic efficacy (Ungaro *et al.,* 2017). Anti-inflammatory agent group partially ameliorated these changes, with slight increases in the glands of Lieberkuhn and some villus shortening (Ungaro *et al.,* 2017). Monoclonal antibody group resulted in reduced goblet cells and slight villus distortion but showed significant improvement in the muscularis layer and glands of Lieberkuhn (Gomollon *et al.,* 2020).

Conclusion

This study demonstrated that acetic acid-induced ulcerative colitis in Sprague Dawley rats leads to significant changes in gut physiology and pathology, including decreased pH, increased total acidity, reduced mucin content, elevated MDA levels, and increased clinical symptoms. The study effectively highlights the significant impacts of antibiotic, anti-inflammatory agent and monoclonal antibody in improving in gut physiology on various parameters associated with UC potentially through the regulation of gastrointestinal secretions, reduction of pro-inflammatory cytokines, which contribute to UC severity, inhibition of oxidative stress, which can damage the gut barrier and exacerbate UC, increase in mucin content, which can protect the gut barrier and reduce UC severity, and modulation of the gut microbiome, which can influence UC severity. The findings indicate that while all the three interventions contribute positively to ameliorating the symptoms and pathological features of UC, their overall efficacy vary.

This study underscores the importance of a tailored therapeutic approach, considering the specific actions and outcome associated with each treatment modalities. Further research should further explore the synergistic potential of this interventions, aiming to enhance treatment strategies for UC and ultimately include treatment outcomes.

References

Ahmad H, Verma S. & Kumar V.L. (2018). Effect of roxithromycin on mucosal damage, oxidative stress and pro-inflammatory markers in experimental model of colitis. *Inflamm. Res.* **67**, 147–155 https://doi.org/10.1007/s00011-017-1103-x

Airola, C., Severino, A., Porcari, S., Fusco, W., Mullish, B. H., Gasbarrini, A., Cammarota, G., Ponziani, F. R., & Ianiro, G. (2023). *Future Modulation of Gut Microbiota: From Eubiotics to FMT, Engineered Bacteria, and Phage Therapy*. *Antibiotics (Basel, Switzerland)*, 12(5), 868. https://doi.org/10.3390/antibiotics12050868

Al-Qahtani, A. A., Alhamlan, F. S., & Al-Qahtani, A. A. (2024). Pro-Inflammatory and Anti-Inflammatory Interleukins in Infectious Diseases: A Comprehensive Review. Tropical Medicine and Infectious Disease, 9(1), 13. https://doi.org/10.3390/tropicalmed9010013

Arijs, I., De Hertogh, G., Lemmens, B., Van Lommel, L., de Bruyn, M., Vanhove, W., Cleynen, I., Machiels, K., Ferrante, M., Schuit, F., et al. (2018). Effect of vedolizumab (anti-α4β7-integrin) therapy on histological healing and mucosal gene expression in patients with UC. *Gut*, 67, 43–52. doi: 10.1136/gutjnl-2016-312293.

Aslam N, Lo SW, Sikafi R., Barnes T, Segal J, Smith PJ & Limdi JK. (2022). A review of the therapeutic management of ulcerative colitis. *Therapeutic advances in gastroenterology*, *15*, 17562848221138160. https://doi.org/10.1177/17562848221138160

Ben-Horin S, Chowers Y. (2014). Tailoring anti-TNF therapy in IBD: drug levels and disease activity. Nat Rev GastroenterolHepatol.11(4):243-255.

Castelli MS, McGonigle P & Hornby PJ. (2019). The pharmacology and therapeutic applications of monoclonal antibodies. *Pharmacology research & perspectives*, *7*(6), e00535.

Chen, C. Y., Hsu, K. C., Yeh, H. Y., & Ho, H. C. (2019). Visualizing the effects of antibiotics on the mouse colonic mucus layer. *Ci Ji Yi Xue Za Zhi = Tzu-Chi Medical Journal*, 32(2), 145–153. https://doi.org/10.4103/tcmj.tcmj_70_19

Collins HH, Cross AS, Dobek A, Opal SM, McClain JB &Sadoff JC. (1989). Oral ciprofloxacin and a monoclonal antibody to lipopolysaccharide protect leukopenic rats

from lethal infection with Pseudomonas aeruginosa. Journal of Infectious Diseases, 159(6), 1073-1082.

Conte, M. P., Schippa, S., Zamboni, I., Penta, M., Chiarini, F., Seganti, L., Osborn, J., Falconieri, P., Borrelli, O., & Cucchiara, S. (2006). Gut-associated bacterial microbiota in pediatric patients with inflammatory bowel disease. *Gut*, 55, 1760–1767.

Corne SJ, Morrissey SM, Woods RJ. (1974). Proceedings: A method for the quantitative estimation of gastric barrier mucus. *J Physiol.* 242:116P–7P.

Cristofori F, Dargenio VN, Dargenio C, Miniello VL, Barone M & Francavilla R. (2021). Anti-inflammatory and immunomodulatory effects of probiotics in gut inflammation: a door to the body. *Frontiers in immunology*, *12*, 578386.

Dinarello CA. (2010). Anti-inflammatory Agents: Present and Future. *Cell*, *140*(6), 935–950. https://doi.org/10.1016/j.cell.2010.02.043

Dorofeyev AE, Vasilenko IV, Rassokhina OA, & Kondratiuk, RB. (2013). Mucosal barrier in ulcerative colitis and Crohn's disease. *Gastroenterology research and practice*, *2013*(1), 431231.

Gomollón F, Dignass A, Annese V & Kucharzik T. (2020). 3rd European evidence-based consensus on the diagnosis and management of Crohn's disease 2016: Part 1: Diagnosis and medical management. Journal of Crohn's and Colitis, 11(1), 3-25.

Hale, L. P., Gottfried, M. R., & Swidsinski, A. (2005). Piroxicam treatment of IL-10-deficient mice enhances colonic epithelial apoptosis and mucosal exposure to intestinal bacteria. *Inflammatory Bowel Diseases*, 11, 1060–1069.

Hauptmann, Hauptmann, Fuchs, Fuchs, Ewe & Ramadori. (1998). Gastrointestinal pH profiles in patients with inflammatory bowel disease. *Alimentary pHarmacology & therapeutics*, *12*(7), 673-678.

Hendrickson, B. A., Gokhale, R., & Cho, J. H. (2002). Clinical aspects and pathophysiology of inflammatory bowel disease. *Clinical Microbiology Reviews*, 15(1), 79–94. https://doi.org/10.1128/CMR.15.1.79-94.2002

Ianiro, G., Tilg, H., & Gasbarrini, A. (2016). Antibiotics as deep modulators of gut

microbiota: between good and evil. Gut, 65(11), 1906-1915.

Iwai T, Ichikawa T, Kida M, Goso Y, Saegusa Y, Okayasu I ... & Ishihara K. (2010). Vulnerable sites and changes in mucin in the rat small intestine after non-steroidal anti-inflammatory drugs administration. *Digestive diseases and sciences*, *55*, 3369-3376.

Kayal M & Shah S. (2019). Ulcerative Colitis: Current and Emerging Treatment Strategies. *Journal of clinical medicine*, *9*(1), 94. https://doi.org/10.3390/jcm9010094

Kotsovilis S & Andreakos E. (2014). Therapeutic human monoclonal antibodies in inflammatory diseases. *Human Monoclonal Antibodies: Methods and Protocols*, 37-59.

Kovacic, P., Somanathan, R. (2014). Inflammation and Anti-Inflammatory Agents – Reactive Oxygen Species and Toxicity. In: Laher, I. (Eds.) *Systems Biology of Free Radicals and Antioxidants*. Springer, Berlin, Heidelberg. https://doi.org/10.1007/978-3-642-30018-9_147

Kucharzik T, Ellul P, Greuter T, Rahier JF, Verstockt B, Abreu C & Sturm A. (2020). ECCO guidelines on the prevention, diagnosis, and management of infections in inflammatory bowel disease. Journal of Crohn's and Colitis, 14(8), 878-898.

Lönnroth, C., Andersson, M., Arvidsson, A., Nordgren, S., Brevinge, H., Lagerstedt, K., & Lundholm, K. (2008). Preoperative treatment with a non-steroidal anti-inflammatory drug (NSAID) increases tumor tissue infiltration of seemingly activated immune cells in colorectal cancer. *Cancer Immunology*, 8, 5.

Lyly, A., Laulajainen-Hongisto, A., Gevaert, P., Kauppi, P., & Toppila-Salmi, S. (2020). Monoclonal Antibodies and Airway Diseases. International Journal of Molecular Sciences, 21(24), 9477. https://doi.org/10.3390/ijms21249477

Lynch WD & Hsu R. (2023). Ulcerative Colitis. In *StatPearls*. StatPearls Publishing.

Marczynski M, Jiang K, Blakeley M, Srivastava V, Vilaplana F, Crouzier T & Lieleg O. (2021). Structural alterations of mucins are associated with losses in functionality. *Biomacromolecules*, *22*(4), 1600-1613.

Matera MG, Page C, Rogliani P, Calzetta L & Cazzola M. (2016). Therapeutic monoclonal

antibodies for the treatment of chronic obstructive pulmonary disease. *Drugs*, *76*, 1257-1270.

McDowell, C., Farooq, U., & Haseeb, M. (2023). Inflammatory Bowel Disease. In *StatPearls*. StatPearls Publishing.

Mukherjee, S., Joardar, N., Sengupta, S., & Sinha Babu, S. P. (2018). Gut microbes as future therapeutics in treating inflammatory and infectious diseases: Lessons from recent findings. The Journal of Nutritional Biochemistry, 61, 111–128. https://doi.org/10.1016/j.jnutbio.2018.07.010

Nemoto H, Kataoka K, Ishikawa H, Ikata K, Arimochi H, Iwasaki T, ... & Yasutomo K. (2012). Reduced diversity and imbalance of fecal microbiota in patients with ulcerative colitis. *Digestive diseases and sciences*, *57*, 2955-2964.

Niv Y. (2016). Mucin gene expression in the intestine of ulcerative colitis patients: a systematic review and meta-analysis. *European Journal of Gastroenterology & Hepatology*, *28*(11), 1241-1245.

Owusu G, Obiri DD, Ainooson GK, Osafo N, Antwi AO, Duduyemi, BM, & Ansah C. (2020). Acetic Acid-Induced Ulcerative Colitis in Sprague Dawley Rats Is Suppressed by Hydroethanolic Extract of *Cordia vignei* Leaves through Reduced Serum Levels of TNF-*α* and IL-6. *International journal of chronic diseases*, *2020*, 8785497. https://doi.org/10.1155/2020/8785497.

Porter RJ, Kalla R, & Ho GT. (2020). Ulcerative colitis: Recent advances in the understanding of disease pathogenesis. *F1000Research*, *9*, F1000 Faculty Rev-294. https://doi.org/10.12688/f1000research.20805.1

Rahier JF, Magro F, Abreu C & Dignass A. (2014). Second European evidence-based consensus on the prevention, diagnosis, and management of opportunistic infections in inflammatory bowel disease. Journal of Crohn's and Colitis, 8(6), 443-468.

Roberts-Thomson IC, Bryant RV & Costello SP. (2019). Uncovering the cause of ulcerative colitis. *JGH open: an open access journal of gastroenterology and hepatology*, *3*(4), 274–276. https://doi.org/10.1002/jgh3.12216

Sakuraba, K., Krishnamurthy, A., Sun, J., Zheng, X., Xu, C., Peng, B., Engström, M., Jakobsson, P. J., Wermeling, F., Catrina, S., Grönwall, C., Catrina, A. I., & Réthi, B. (2022). Autoantibodies targeting malondialdehyde-modifications in rheumatoid arthritis regulate osteoclasts via inducing glycolysis and lipid biosynthesis. *Journal of Autoimmunity*, 133, 102903. https://doi.org/10.1016/j.jaut.2022.102903

Sandborn WJ, Feagan BG, Wolf DC & Lichtenstein GR. (2021). Ozanimod induction and maintenance treatment for ulcerative colitis. New England Journal of Medicine, 385(14), 1280-1291.

Schreiber F, Balas I, Robinson MJ, Bakdash G. (2024) Border Control: The Role of the Microbiome in Regulating Epithelial Barrier Function. *Cells* , *13*, 477. https://doi.org/10.3390/cells13060477

Shandilya, S., Kumar, S., Kumar Jha, N., Kumar Kesari, K., & Ruokolainen, J. (2021). Interplay of gut microbiota and oxidative stress: Perspective on neurodegeneration and neuroprotection. *Journal of Advanced Research*, 38, 223–244. https://doi.org/10.1016/j.jare.2021.09.005

Shi, Y., Luo, J., Narbad, A., & Chen, Q. (2023). Advances in Lactobacillus Restoration for β-Lactam Antibiotic-Induced Dysbiosis: A System Review in Intestinal Microbiota and Immune Homeostasis. Microorganisms, 11(1), 179. https://doi.org/10.3390/microorganisms11010179

Subramanian S, Du C & Tan XD. (2022). Can Rodent Model of Acetic Acid-Induced Colitis be Used to Study the Pathogenesis of Colitis-Associated Intestinal Fibrosis?. *Journal of investigative surgery : the official journal of the Academy of Surgical Research*, *35*(1), 223–224. https://doi.org/10.1080/08941939.2020.1821845.

Świrkosz G, Szczygieł A, Logoń K, Wrześniewska M, Gomułka K. (**2023)** The Role of the Microbiome in the Pathogenesis and Treatment of Ulcerative Colitis—A Literature Review. *Biomedicines* , *11*, 3144. https://doi.org/10.3390/biomedicines11123144.

Sydora, B. C., MacFarlane, S. M., Walker, J. W., Dmytrash, A. L., Churchill, T. A., Doyle, J., & Fedorak, R. N. (2007). Epithelial barrier disruption allows non-disease-causing

bacteria to initiate and sustain IBD in the IL-10 gene-deficient mouse. *Inflammatory Bowel Diseases*, 13, 947–954.

Triantafyllidis A, Charalambous S, Papatsoris AG. (2005). Management of nocturnal enuresis in Greek children. Pediatr NepHrol 20, 1343–1345. https://doi.org/10.1007/s00467-005-1921-x

Ungaro R, Mehandru S, Allen PB, Peyrin-Biroulet L & Colombel JF. (2017). Ulcerative colitis. *Lancet (London, England)*, *389*(10080), 1756–1770. https://doi.org/10.1016/S0140-6736(16)32126-2

Ungaro R, Mehandru S, Allen PB, Peyrin-Biroulet L & Colombel JF. (2019). Ulcerative colitis. The Lancet, 389(10080), 1756-1770.

Witaicenis A, Luchini AC, Hiruma-Lima CA, Felisbino SL, Garrido-Mesa N, Utrilla P, et al. Suppression of TNBS-induced colitis in rats by 4-methylesculetin, a natural coumarin: Comparison with prednisolone and sulpHasalazine. Chem Biol Interact. 2012;195(1):76–85. pmid:22119283.

Yang, S., Qiao, J., Zhang, M., Kwok, L. Y., Matijašić, B. B., Zhang, H., & Zhang, W. (2024). Prevention and treatment of antibiotics-associated adverse effects through the use of probiotics: A review. *Journal of Advanced Research*. Advance online publication. https://doi.org/10.1016/j.jare.2024.06.006

Zakaria Z, Hisam EA, Rofiee M, Norhafizah M, Somchit M, Teh L and Salleh M. (2011). In vivo antiulcer activity of the aqueous extract of Bauhinia purpurea leaf. J Ethnopharmacol 137: 1047-1054.

Zhang, J. M., & An, J. (2007). Cytokines, inflammation and pain. International Anesthesiology Clinics, 45, 27–37. doi: 10.1097/aia.0b013e318034194e

Zhou W, Huang Y, Lai J, Lu J, Feely M & Liu X. (2018). Anti-inflammatory biologics and anti-tumoral immune therapies-associated colitis: a focused review of literature. *Gastroenterology Research*, *11*(3), 174.