Antioxidative Stress And Hepatoprotective Activities Of Leaf Extract And Fractions OF *Saccharum officinarum* in *Plasmodium berghei* Infected Mice

Utibe A. Edem[1], Jude E. Okokon[1*], Augustine I. Bassey[2], Patience J. Okokon[3]

[1]Department of Pharmacology and Toxicology, University of Uyo, Nigeria
[2]Department of Clinical Pharmacology and Therapeutics, University of Uyo, Nigeria
[3]Department of Clinical Pharmacy and Biopharmacy, University of Uyo, Nigeria
Submitted:8th June, 2022;Accepted:11th Aug, 2022; Available online: 31st Aug, 2022

Doi: https://doi.org/10.54117/jcbr.v2i4.8
*corresponding author: judeefiom@yahoo.com; +234-8023453678

Abstract

Saccharum officinarum (Family-Poaceae) is used in Ibibio ethnomedicine for the treatment of various diseases such as malaria. The leaf extract and fractions of *S. officinarum* were investigated for antioxidative stress and hepatoprotective activities in *Plasmodium berghei*-infected mice using early infection test model. Antioxidative stress and hepatoprotective potentials were assessed by determining oxidative stress markers levels, liver function indices and histopathology of liver. The leaf extract (170-510 mg/kg, p.o.) exerted significant ($p<0.05$) antimalarial activity against *P. berghei* infection in suppressive tests with *n*-hexane and butanol fractions having the highest activity. The leaf extract and fractions also caused significant ($p<0.05$) increases in the levels of oxidative stress markers enzymes and molecules (CAT, GPx, GST) with no significant ($p>0.05$) effect on GSH, SOD and MDA levels in the liver of the treated infected mice. The extract/fractions treatment caused significant ($p<0.05$) reductions in liver enzymes (ALT, AST and ALP), total and conjugated bilirubin of the treated infected mice. Histology of liver revealed absence or significant reductions in pathological features in the treated infected mice compared to untreated infected mice. These results suggest that the leaf extract/fractions of *S. officinarum* possess antioxidative stress and hepatoprotective potentials which gives credence to its use in the treatment of malaria.

Keywords: Malaria, *Saccharum officinarum, Plasmodium berghei,* antioxidative stress, hepatoprotective

Introduction

According to the World malaria report of 2020, there were an estimated 229 million malaria cases in 2019 in 87 malaria endemic countries globally (WHO. 2020). Although, there was a decline in mortality due to malaria, Nigeria still recorded the highest mortality rate of all malaria deaths globally in 2019. In spite of the successes achieved in the global fight against malaria over the last two decades, malaria still threatens most countries of Africa particularly Nigeria. Oxidative stress associated with malaria infection, though poorly understood (Agbafor *et al.*, 2015), has been implicated in the pathogenesis

and development of systemic complications caused by malaria (Guha *et al.,* 2006; Ojezele *et al.,* 2017). Malaria complications including anemia, jaundice and pre-eclampsia have been linked to oxidative stress damage caused by the parasite (Fabbri *et al.,* 2013; Sarr *et al.,* 2017). Medicinal plants are a great source of antimalarial drugs including the front-line drug artemisinin, having the advantage of being safer and providing many therapeutic effects.

Saccharum officinarum (Family-Poaceae) commonly known as sugarcane is found throughout tropical and subtropical regions worldwide. It is employed traditionally in the treatment of diarrhoea, dysentery, eyes, fever, arthritis, bedsores, boils, cancer, colds, cough, opacity, skin sores, sore throat, hiccups, inflammation, laryngitis, spleen, tumors, and wounds (Hartwell, 1967-1971). Biological activities reported on the leaf include antibacterial and anthelmintic (Palaksha *et al.,* 2013), anti-hyperglycaemic, anti-hyperlipidaemic (Ojewunmi *et al.,* 2013), antioxidant (Ojewunmi *et al.,* 2013; Sun *et al.,* 2014). Diuretic and antiurolithiatic (Palaksha *et al*., 2015), antidepressant and anticonvulsant (Okokon *et al.,* 2019), analgesic (Okokon et al., 2021) and antimalarial (Okokon et al., 2022) activities. SAABMAL®: an ethnomedicinal polyherbal formulation containing *S. officinarum* has been used for the treatment of uncomplicated malaria infection in Nigeria (Obidike *et al.,* 2015). It is also used alone in the treatment of malaria in the Dangme West District of Ghana (Akwetey and Achel, 2010). Phytochemical screening of leaf extract of *Saccharum officinarum* reported the presence of glycosides, phytosterols, saponins, tannins, flavonoids, (Palaksha *et al.,* 2013; Singh *et al*., 2015). Coutinho et al.(2016) had identified some flavones and phenolics as well as their derivatives from the leaves of *S. officinarum*. However, there is no evaluation of its antioxidative stress and hepatoprotective potentials. We report for the first time the antioxidative stress and hepatoprotective activities of the leaf extract and fractions of *Saccharum officinarum.*

Materials and methods

Plant materials

Fresh leaves of *Saccharum officinarum* were collected in June, 2020 from residential quarters in Uyo village in Uyo LGA, Akwa Ibom State, Nigeria. The leaves were identified and authenticated as *Saccharum officinarum* by a taxonomist in the Department of Botany and Ecological studies, University of Uyo, Uyo, Nigeria and a voucher specimen (UUPH 215b) was prepared and deposited at the herbarium of the Department of Pharmacognosy and Natural Medicine, Faculty of Pharmacy, University of Uyo.

Extraction

Fresh leaves of *S. officinarum* were washed, cut into smaller pieces and dried under shade for two weeks. The leaves were further pulverized to

powder using electric grinder. The powdered leaf material (2 kg) was soaked in 50% ethanol (7.5 L) at room temperature (28 ± 2 ˚C) for 72 hours. It was thereafter filtered and the liquid filtrate was concentrated and evaporated to dryness in *vacuo* 40 ˚C using a rotary evaporator (BuchiLab Switzerland). The crude extract (50.0 g) was dissolved in water (200 mL) and partitioned using n-hexane, dichloromethane, ethyl acetate and *n*-butanol (4 x 500 mL each) to give the corresponding fractions of these solvents. The extract and fractions were weighed and stored in a refrigerator at -4 ˚C, until used for the proposed experiments.

Microorganism (parasite)

The chloroquine-sensitive strain of *Plasmodium berghei* (ANKA strain) was obtained from the National Institute of Medical Research (NIMER), Yaba Lagos, Nigeria and maintained by subpassage in mice.

Parasite inoculation

The inoculum used in this study consisted of 5 x 10^7 *P. berghei* parasitized erythrocytes per milliliter and was prepared by diluting the blood with isotonic saline in proportions indicated from determination of both the percentage parasitemia and the erythrocytes count of the donor mouse (Okokon *et al*., 2022). In the experiment, each mouse was inoculated intraperitoneally with 0.2 mL of infected blood containing about 1 x 10^7 *P. berghei* parasitized erythrocytes.

Experimental animals

Swiss albino mice (18-25 g), male and female, used in the study were obtained from the University of Uyo's animal house. They were kept in standard plastic cages in a well ventilated room and left to acclimatized for a period of 10 days before the experiments. The mice were fed on standard pelleted diet and water *ad libitum*. The care and use of animals were conducted in accordance with the National Institute of Health Guide for the Care and Use of laboratory Animals (NIH Publication, 1996). Approval for the study was obtained from the University of Uyo's Animal Ethics Committee (UU/CHS/AE/21/068).

Drug administration

The extract, fractions, and chloroquine that were used in the study were administered orally with the aid of a stainless metallic feeding cannula.

Evaluation of antioxidative and liver protective activities of the leaf extract and fractions of Saccharum officinarum using 4-day test

The evaluation was carried out using the method earlier described by Udobang *et al.* (2017). On the first day (D_0), forty five mice were infected with *P. berghei* parasite and randomly divided into nine groups of five (5) mice each. Based on the LD_{50} value of 1732 mg/kg determined previously (Okokon *et al*., 2022), the mice in groups 1-3 were given 170 mg/kg, 340 mg/kg and 510 mg/kg of crude extract respectively, while groups 4-7 were

administered 340 mg/kg of *n*-hexane, dichloromethane, ethyl acetate, and *n*-butanol fractions respectively, group 8 was administered 5 mg/kg of chloroquine (positive control) and group 9 was given 10 mL/kg of distilled water (negative control) for four consecutive days (D_0-D_3) between 8am to 9am. On the fifth day (D_4), thin films were made from the tail blood. The films were stained with Giemsa stain to reveal parasitized erythrocytes out of 500 erythrocytes in a random field of the microscope. On the tenth day, the mice were sacrificed under diethyl ether vapour. Blood was collected into EDTA bottles and plain centrifuge tubes. The blood samples in the EDTA bottles were used for haematological analysis, while those in centrifuge tubes were centrifuged immediately at 2500 rpm for 15 mins to separate the serum at room temperature and stored at -20°C until used for biochemical determinations. Liver from each mouse was surgically removed, weighed and divided into two parts. One part was fixed in 10% formaldehyde for histological process and the other part stored in ice cold normal saline. The average suppression of parasitemia was calculated according to the formula of Peters and Robinson (1992) as follows: (average % parasitemia positive control – average % parasitemia negative control) / (average % parasitemia negative control).

Effect of the leaf extract and fractions on liver function parameters of P. berghei infected mice

Liver function parameters such as total protein, albumin, aspartate aminotransferase(AST), alanine aminotransferase (ALT), alkaline phosphotase(ALP), conjugated and total bilirubin were determined in the stored serum from each sacrificed mouse spectrophotometrically using Randox analytical kits according to standard procedures of manufacturer's protocols (Tietz, 1976).

Determination of the effect of the leaf extract and fractions on the lipid profile of the treated P. berghei infected mice

Serum total cholesterol, triglyceride and high density lipoprotein (HDL) levels of the diabetic rats were measured by enzymatic colorimetric methods using Randox diagnostic kits. The low and very low-density lipoprotein (LDL and VLDL) were estimated from the formula of Friedwald *et al.,* (1972).

Effect of the leaf extract and fractions on liver antioxidative stress markers of P. berghei infected mice

The excised livers were stored and washed with ice cold 0.9% NaCl. Homogenates were made in a ratio of 1 g of wet tissue to 9 ml of 1.25% KCl by using motor driven Teflon-pestle. The homogenates were centrifuged at 7000 rpm for 10 min at 4˚C and the supernatants were used for the assays of superoxide dismutase (SOD) (Marklund and Marklund, 1974),

catalase (CAT) (Sinha,1972), glutathione peroxidase (GPx) (Lawrence and Burk,1976), and reduced glutathione (GSH) (Ellman,1959).

Effect of leaf extract and fractions on haematological indices Plasmodium berghei-infected mice.

The blood samples collected into ethylene diamine tetra-acetic acid (EDTA) – coated bottles were analyzed for parameters such as red blood cell count (RBC), hemoglobin, (Hb), packed cell volume (PCV), platelet concentration (PLC) and total and differential white blood cell count (WBC). These parameters were analyzed using automatic hematological system (Sysmex Hematology – Coagulation system, Model MO-1000 I, Trans Asia, Japan).

Effect of the leaf extract and fractions on liver histology of P. berghei infected mice

The liver parts of mice that were fixed in buffered formalin were processed and stained with haematotoxylin and eosin (H&E) for liver study according to standard procedures at Department of Chemical Pathology, University of Uyo Teaching Hospital, Uyo. Morphological changes observed and recorded in the excised organ of the sacrificed mice. Histologic pictures were taken as micrographs.

Statistical analysis

Data collected were analyzed using one way analysis of variance (ANOVA) followed by Tukey's multiple comparison post-test (Graph pad prism software Inc. La Jolla, CA, USA). Values were expressed as mean ± SEM and significance relative to control were considered at $p<0.05$.

Results

Effect of ethanol leaf extract and fractions of S. officinarum on parasitaemia

The extract and its fractions exerted dose-dependent reductions in parasitaemia of the treated mice in various groups. These reductions were statistically significant relative to the control ($p<0.05$). The *n*-butanol fraction demonstrated the highest suppressive activity. (Figure 1).

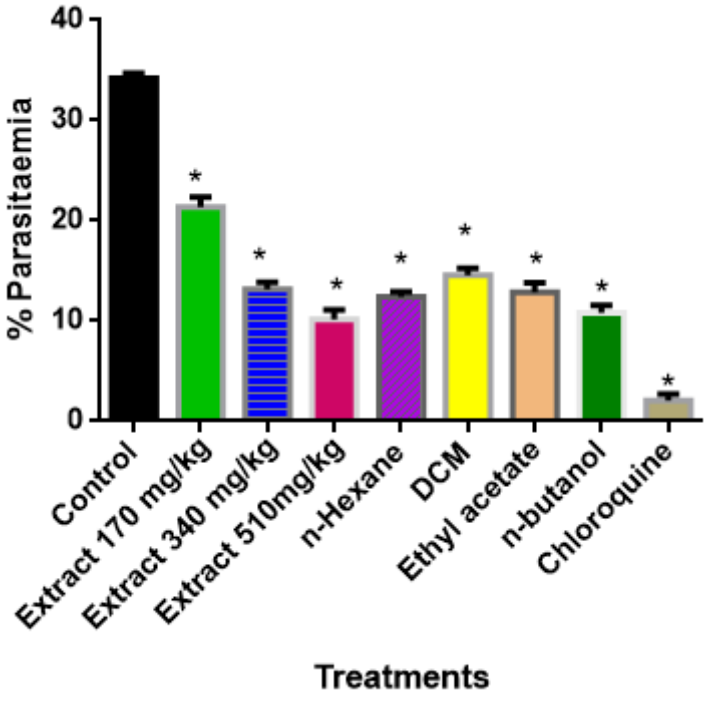

Figure 1: Effect of leaf extract and fractions of *S. officinarum* on early *P. berghei* infection in mice. Values are expressed as mean ± SEM. Significant relative to control. *$p<0.05$ n = 6.

Effect of leaf extract and fractions on liver function parameters of Plasmodium berghei-infected mice.

The levels of liver function indices (AST, ALT, ALP, total protein, albumin, total and conjugated bilirubin) were found to be elevated in untreated *P. berghei* -infected mice. However, treatment of *P. berghei* infected mice with leaf extract and fractions of *S. officinarum* caused non dose-dependent and significant ($p<0.05$) reductions in the levels of AST, ALT, ALP, total and conjugated bilirubin. DCM fraction had the highest significant ($p<0.05$) effect compared to control. This is followed by methanol and ethyl acetate fractions treated groups . Some of the effects were better than those of chloroquine-treated group (Table 1). The reduction of total protein and albumin levels of the treatment groups was significant ($p<0.05$) but it was not dose-dependent. The reductions were significant at the doses of 170 and 510 mg/kg (Table 1).

Effect of leaf extract and fraction on liver antioxidative stress markers of Plasmodium berghei-infected mice.

Treatment of *Plasmodium berghei*-infected mice with leaf extract and fractions *of S. officinarum* did not cause significant ($p>0.05$) effect on the levels of GSH, SOD and MDA when compared to control. However, the levels of GPX, CAT and GST were found to be significantly ($p<0.05$) and non dose-dependently increased when compared to control especially in the groups treated with the extract, DCM

and n-hexane fractions. Chloroquine was also found to increase the levels of CAT and GST significantly ($p<0.05$) when compared to control (Table 2).

Effect of extract and fractions on the lipid profile of Plasmodium berghei-infected mice.

Administration of leaf extract and fractions of *S. officinarum* to *P. berghei*-infected mice caused non dose-dependent and significant ($p<0.05$) decreases in the TC level when compared to control. The highest effect was observed with DCM fraction. A non-dose dependent reductions were also observed in TG level following the leaf extract and fractions treatment. This was only significant ($p<0.05$) in the group treated with DCM fraction when compared to control. The leaf extract/fractions treatment also caused decrease in the levels of LDL of infected mice. These decreases were non dose-dependent and significant ($p<0.05$) in groups treated with the extract (170, 340 and 510 mg/kg) and DCM fraction when compared to control. The extract and fractions also caused non dose-dependent and non significant ($p<0.05$) reductions in the level of VLDL when compared to control. However, there was a non dose-dependent increases in HDL level following the extract/fractions treatment. This was only significant ($p<0.05$) in the group treated with DCM fraction when compared to control (Table 3).

Table 1: Effect of leaf extract and fractions of *Saccharum officinarum* on liver function parameters of mice infected with *Plasmodium berghei*

Treatment	Dose (mg/kg)	LIVER FUNCTION PARAMETERS						
		AST (IU/L)	ALT(IU/L)	ALP(IU/L)	Total protein (g/L)	Albumin (g/L)	Total bilirubin (µmol/mL)	Conjugated bilirubin (µmol/mL)
Control	-	33.33±1.84	27.46 ±1.35	31.6 ±1.06	69.6 ±3.38	48.0 ±2.08	8.53±0.63	8.20±0.55
Extract	170	27.33±1.76	17.76±0.72[a]	12.40±1.32[a]	61.33±0.88[a]	40.0±1.15[a]	5.90±0.20[a]	3.46±0.28[a]
	340	25.33±1.45[a]	21.93±4.55[a]	22.86±5.78[a]	68.0±2.51	44.33±1.45	5.16±0.32[a]	3.03±0.14[a]
	510	25.66±2.60[a]	17.16±0.44[a]	13.53±1.71[a]	59.66±1.20[a]	38.33±0.88[a]	5.16±0.52[a]	2.83±0.20[a]
n-hexane	340	26.33±1.85[a]	19.96±1.10[a]	15.26±3.09[a]	66.66±0.88	45.0 ±1.15	5.20±0.47[a]	3.56±0.57[a]
Dichloromethane	340	21.66±1.20[a]	17.83±1.09[a]	10.93±0.50[a]	63.0 ±1.15	42.33 ±1.45	4.50±0.17[a]	2.83±0.08[a]
Ethyl acetate	340	26.40±1.02[a]	18.76±1.49[a]	11.03±1.45[a]	68.33±2.96	45.33 ±1.45	5.63±0.44[a]	3.76±0.50[a]
n-butanol	340	26.33±1.60[a]	16.43±1.58[a]	20.90±1.59[a]	68.0 ±1.52	44.0 ±2.80	5.60±0.58[a]	3.63±0.32[a]
Chloroquine	5	25.66±1.90[a]	15.36±0.85[a]	18.16 ±4.41[a]	52.0±1.73[a]	35.66±1.85[a]	5.30±0.55[a]	3.73±0.57[a]

Values are expressed as mean ± SEM. Significant relative to control. [a]$p<0.05$; [b]$p<0.01$; [c]$p<0.001$. n = 6.

Table 2: Effect of leaf extract and fractions of *Saccharum officinarum* on liver antioxidant enzymes of mice infected with *Plasmodium berghei* .

Treatment	Dose (mg/kg)	ANTIOXIDANT PARAMETERS						
		GSH(µg/mL)	SOD(µg/mL)	CAT(µg/mL)	GPX (µm/mL)	GST(µg/mL)	MDA (µmol/mL)	Liver weight (g)
Control	-	1.16±0.15	0.17 ±0.02	1.03 ±0.03	0.033 ±0.002	0.074 ±0.002	0.57±0.01	2.91±0.12
Extract	170	0.83±0.08	0.15±0.01	1.50±0.38[a]	0.038±0.003	0.090±0.001[a]	0.59±0.02	2.46±0.11
	340	1.10±0.36	0.15±0.01	1.33±0.15	0.052±0.001[a]	0.080±0.003[a]	0.55±0.01	2.33±0.10
	510	1.14±0.16	0.16±0.02	0.89±0.24	0.051±0.007[a]	0.050±0.002[a]	0.58±0.02	2.28±0.13
n-hexane	340	0.83±0.05	0.18±0.01	1.50±0.29[a]	0.037±0.002[a]	0.100 ±0.003[a]	0.55±0.02	2.41±0.14
Dichloromethane	340	1.20±0.14	0.16±0.01	1.82±0.24[a]	0.049 ±0.001[a]	0.120 ±0.002[a]	0.57±0.01	2.20±0.15
Ethyl acetate	340	0.98±0.05	0.17± 0.02	0.90± 0.10	0.043 ±0.002	0.060 ±0.002	0.57±0.02	2.40±0.16
n-butanol	340	0.84±0.05	0.15± 0.03	1.31± 0.35	0.038 ±0.002	0.110 ±0.001[a]	0.60±0.02	2.31±0.14
Chloroquine	5	1.18 ±0.04	0.15 ±0.01	2.73 ±0.39[a]	0.038±0.003	0.155±0.01[a]	0.56±0.04	2.21±0.16

Values are expressed as mean ± SEM. Significant relative to control. [a]$p<0.05$. n = 6.

Table 3: Effect of leaf extract and fractions of *Saccharum officinarum* on lipid profile of mice infected with *Plasmodium berghei* .

TREATMENT	DOSE mg/kg	TOTAL CHOLESTEROL (mMol/L)	TRIGLYCERIDE (mMol/L)	HDL-C (mMol/L)	LDL-C (mMol/L)	VLDL (mMol/L)
Control	10 mL/kg	3.66± 0.29	1.47± 0.08	1.12± 0.07	2.91± 0.26	0.67± 0.06
Crude extract	170	2.33±0.29[a]	1.18± 0.24	1.50± 0.23	1.71± 0.40[a]	0.53± 0.11
	340	2.66± 0.14 [a]	1.07± 0.03	1.88± 0.02[a]	1.27± 0.12[a]	0.48± 0.01
	510	2.70± 0.15 [a]	1.18± 0.08	1.62± 0.13	1.61± 0.21[a]	0.54± 0.04
n-hexane	340	2.93± 0.12	1.34± 0.18	1.18± 0.04	2.36± 0.14	0.61± 0.08
Dichloromethane	340	2.73± 0.23[a]	0.85± 0.11[a]	1.42± 0.16	1.83± 0.18[a]	0.38± 0.05
Ethyl Acetate	340	2.86± 0.21	1.28± 0.04	1.32± 0.04	2.27± 0.20	0.58± 0.02
n-butanol	340	2.76± 0.16[a]	1.05± 0.05	1.17± 0.03	2.12± 0.18	0.48± 0.01
Chloroquine	5	3.53± 0.18	1.37± 0.36	1.50± 0.18	2.60± 0.16	0.62± 0.16

Data is expressed as MEAN ± SEM, Significant at [a]$p<0.05$ when compared to control. (n=6).

TABLE 4: Effect of *Saccharum officinarum* leaf extract/fractions on haematological parameters of *P. berghei*-infected mice

Treatment	WBC ($x10^9$/L)	LYM ($x10^9$/L)	NEUT ($x10^9$/L)	RBC ($x10^{12}$/L)	HGB (g/dL)	PCV (%)	MCV (fL)	MCH (pg)	MCHC (g/dL)	PLT ($x10^9$/L)
Control	14..50±4.0	32.53±2.5	65.57±1.52	5.34±0.35	8.43±0.96	38.07±2.43	75.07±0.62	11.83±0.09	30.13±0.33	454.33±64.32
Extract (170 mg/kg)	7..53±0.3[a]	58.42±6.9	35.56±3.1[a]	7.84±1.35	11.22±0.34	44.56±4.28	50.34±1.38[a]	12.20±0.34	25.60±1.30	664.32±54.0[a]
Extract (340mg/kg)	7.14±0.1[a]	44.33±5.8	48.10±4.18	8.36±1.2[a]	13.15±0.23	50.04±0.52[a]	44.01±0.56[a]	13.12±0.29	24.15±1.23	701.10±65.3[a]
Extract (510mg/kg)	6.10±0.1[a]	48.44±8.4[a]	50.38±8.5[a]	8.04±1.2[a]	12.50±0.11[a]	56.35±3.15[a]	62.10±8.92	11.02±1.25	25.00±3.19	976.48±48.6[a]
Hexane fraction	9.35±1.1[a]	46.86±1.3[a]	44.84±5.3[a]	8.11±1.0[a]	13.62±0.42[a]	53.22±4.15[a]	56.20±7.10[a]	13.25±1.80	26.82±1.54	528.48±60.3[a]
Dichloromethane fraction	6.55±0.5[a]	55.00±6.0[a]	40.39±4.9[a]	8.50±0.1[a]	13.73±0.58[a]	50.16±2.60[a]	50.54±3.20[a]	13.32±0.64	24.82±3.24	759.64±40.1[a]
Ethyl acetate fraction	10.32±1.8	43.02±5.4	50.45±5.3[a]	8.45±0.3[a]	13.58±1.52[a]	62.36±4.86[a]	55.93±3.20[a]	12.86±0.23	24.22±0.84	624.74±24.20
n-butanol Fraction	8.96±2.3[a]	45.84±5.6	53.29±5.92	8.02±0.45	12.05±0.35	48.13±4.28[a]	51.74±3.40[a]	12.11±0.60	24.81±2.48	935.28±49.3[a]
Chloroquine	9.58±1.39	40.66±0.0	46.34±0.39	8.53±0.2[a]	12.94±0.70[a]	48.72±1.22[a]	59.40±0.84[a]	18.88±0.27[a]	25.68±0.71	631.40±44.7[a]

All values are presented as mean±S.E.M. for six rats in each group. Significant at [a] $p<0.05$ when compared with control group .

Effect of extract and fractions on the histology of liver of Plasmodium berghei-infected mice.

Histological sections of livers of untreated infected mice adminstered distilled water (10 mL/kg) at magnification (X400) revealed distorted liver with congested central vein, hepatocytes, Sinusoids containing inflammatory cells and necrotic tissues, while livers of infected mice treated with 170 mg/kg of leaf extract revealed distorted liver with Sinusoids containing Kupffer cells and necrotic tissues (Figure 2). However, livers of infected mice treated with 340 and 510 mg/kg of extract revealed normal hepatocytes with patent central vein and Sinusoids containing Kupffer cells (Figure 2). Livers of infected mice treated with *n*-hexane fraction and chloroquine showed normal liver sections with intact hepatocytes, patent central vein and Sinusoids containing Kupffer cells, while infected mice treated with DCM, ethyl acetate and *n*-butanol fractions had liver histologic sections showing distorted liver with hepatocytes, Sinusoids containing kupffer cells, cappillaries and necrotic tissue (figure 2).

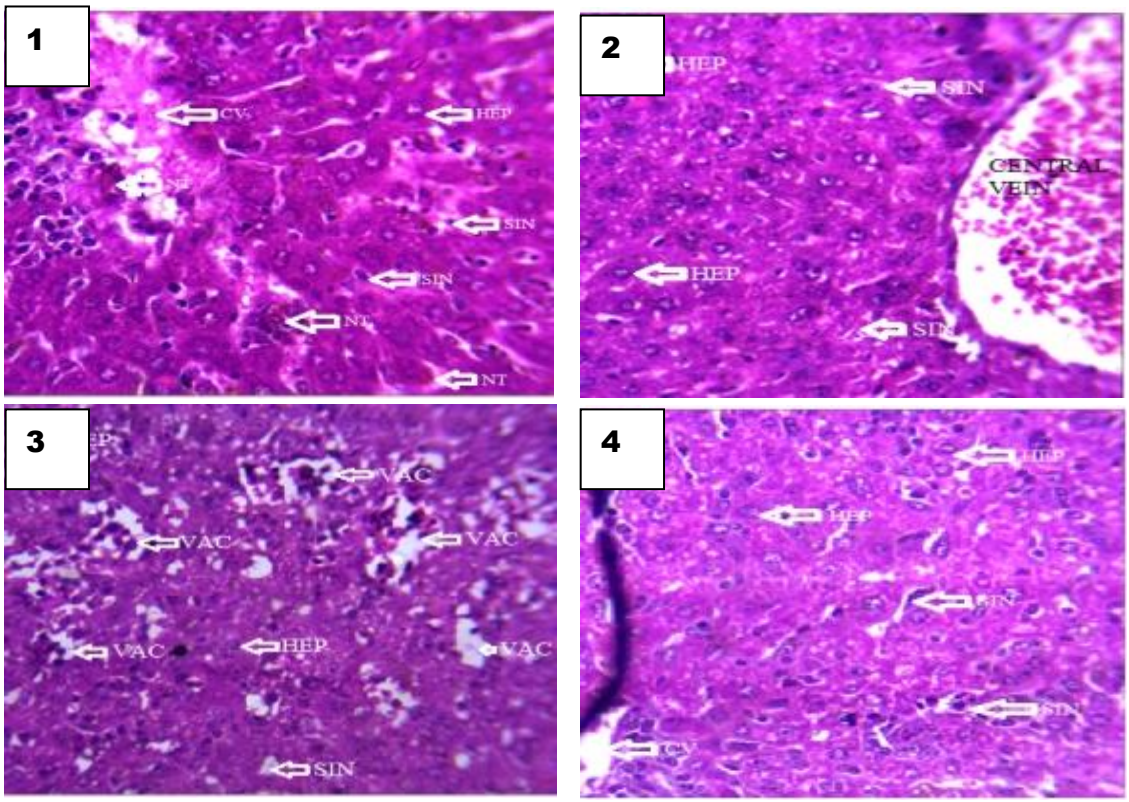

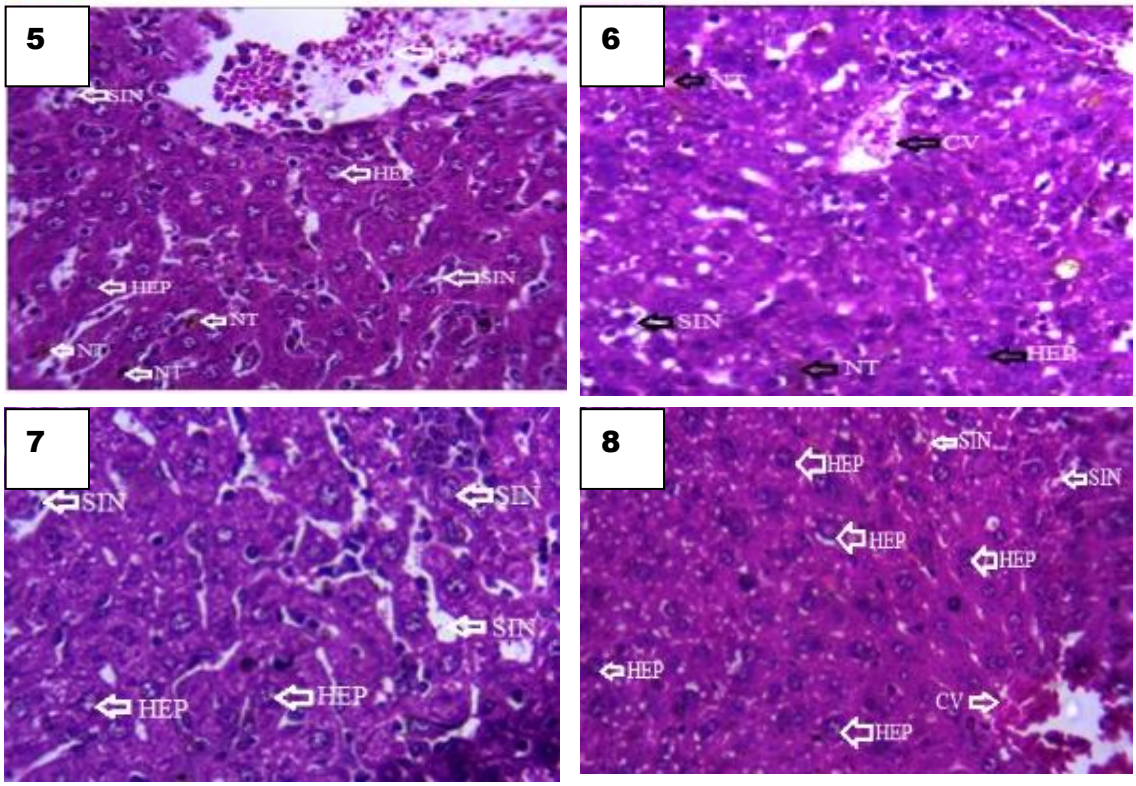

Figure 2: Histologic Liver sections of *Plasmodium berghei*-infected mice untreated with normal saline (1), leaf extract of *S. officinarum*, 170 mg/kg (2), 340 mg/kg (3), 510 mg/kg (4), n-hexane fraction(5), DCM fraction (6), ethyl acetate fraction (7), n-butanol fraction (8) and chloroquine, 5 mg/kg (9) at magnification X400. Keys: Hepatocytes (HEP), Sinusoids (SIN), Necrotic tissues (NT), Steatosis (ST), Inflammatory cells (INF), Vacuolations (VAC), congested central vein (CV).

Effect of leaf extract and fractions on haematological indices Plasmodium berghei-infected mice.

Administration of the leaf extract and fractions to *P. berghei*-infected mice caused significant ($p<0.05$-0.001) increase in RBC, lymphocytes and platelets counts, Hb concentration, PCV percentages and MCH levels when compared to untreated infected mice though non dose-dependently. The elevated WBC counts and neutrophils percentages in the untreated infected animals were reduced significantly ($p<0.05$-0.001) in the treated infected animals when

compared statistically. However, the MCV and MCHC percentages were not affected significantly ($p>0.05$) when compared with the untreated infected mice (Table 4).

DISCUSSION

In this study, it was found that the extract and fractions significantly reduced the parasitaemia in a dose-dependent fashion with *n*-butanol fraction exhibiting the highest schizonticidal activity confirming the antimalarial potential of this extract. This activity could have resulted from the activities of the phytochemical constituents of extract and fractions, validating the local use of the leaf extract decoctions as malarial remedy.

Secondary metabolites and other chemical constituents of plants are known to be responsible for antimalarial activities of plants. The reported chemical constituents of the leaves extract under study include tannins, flavonoids, alkaloids, terpenes, triterpenes like squalene, phenolics, β-sitosterol and polyunsaturated fatty acids (PUFAs), 3,4,5-trihydroxy benzoic acid (gallic acid), β-sitosterol, *p*-coumaric acid (4-hydroxycinnamic acid) and tricin-7-O-eohesperoside (Okokon *et al.*, 2022) among others. These compounds are likely to be responsible for the observed activities of the extract and fractions especially the flavonoids and PUFAs which have been implicated previously in antiplasmodial properties of plants (Ganesh *et al.*, 2012;Attioua *et al.*, 2007; Melariri *et al.*, 2011, 2012). Flavonoids and derivatives reported to be present in the leaf extract (Coutinho *et al.*, 2016; Okokon *et al.*, 2022), have been shown to possess significant antiplasmodial activity against chloroquine sensitive and resistant strains of *P. falciparum* (Attioua *et al.*, 2011; Ganesh *et al.*, 2012; Ezenyi *et al.*, 2014).

Effect of the extract and fractions on the livers' histology of the *P. berghei*-infected mice was also investigated to assess their hepatoprotective potentials. Higher levels of transaminases and hyperbilirubinemia were observed in the untreated infected mice which are indicative of liver injuries. These features are common during malaria infection and could result from obstruction of hepatic blood and blockade of Sinusoids by parasitized erythrocytes. Moreso, generation of free radicals during malaria infection could also cause destruction of the liver cells and membranes integrity, while reticuloendothelial blockage and disturbance of hepatocyte microvilli could compromised the secretory capacity in the liver thereby resulting in hyperbilirubinemia (Onyesom and Onyemakonor, 2011). Administration of leaf extract and fractions of *S. officinarum* to *P. berghei*-infected mice was found to reduce the elevated total protein, albumin, AST, ALT, ALP, total and conjugated bilirubin. This is indicative of hepatoprotective activity of the leaf extract. Besides, the histological analysis of liver from malaria infected mice showed a significant pathologic signs such as general architectural disorganization of liver architecture with inflammatory

sites, hepatocyte necrosis, vascular congestion, and Sinusoids contained in Kupffer cells (figure 2). These were reduced or absent following extract/fractions treatments which further confirm the hepatoprotective activity of the leaf extract due to the antioxidant activities of its phytochemical constituents.

Oxidative stress contributes to complications associated with malaria infection such as anemia, jaundice and pre-eclampsia (Fabbri *et al.,* 2013; Sarr *et al.,* 2017). Large amount of free radicals are generated due to the hypoxic condition caused by malaria infection which triggers body immune responses (Becker *et al.,* 2004; Percario *et al.,* 2012), leading to the development of systemic complications associated with malaria (Guha *et al.,* 2006; Ojezele *et al.,* 2017). Malarial infection has been observed to reduce the levels of antioxidant enzymes and other non enzymatic anti-oxidants such as catalase (CAT), glutathione (GSH) peroxidase, super oxide dismutase (SOD), albumin, ascorbate and plasma tocopherol. Severity of malaria disease has been correlated with increased lipid peroxidation and malondialdehyde levels (Asagba *et al*., 2010; Adil *et al*., 2013), hence used to measure the severity of malaria infection. In this study, the activities of CAT, GPx and GST level which were found to decrease significantly in the untreated infected mice were elevated by the extract /fractions treatment, while GSH and MDA levels, and SOD activity was not significantly affected by the treatment when compared to the untreated infected group. The plant extract and fractions exerted antioxidative stress potentials by increasing the levels of some antioxidative stress markers. This activity can be explained to results from the antioxidant activities of phenols, flavonoids and other derivatives such as squalene, a triterpene, hexadecanoic acid and sitosterol present in the leaf extract (Coutinho *et al.,* 2016; Okokon *et al.,* 2022), which are potent antioxidant compounds (Kohno *et al.,* 1995; Ponnamma and Manjunath, 2012; Khan and Siddique, 2019).

Besides, malaria infection also induced oxidative modification of lipoproteins thereby contributing to oxidative stress, progression and complications of malaria infections (Nathawut *et al*., 2004; Krishna *et al*., 2009). Lipid metabolism alteration has been attributed to acute phase response to the infection (Memon *et al*., 2000). Treatment with *S. officinarum* caused a significant ($p<0.05$) reduction in the elevated serum concentration of total cholesterol (TC), triglyceride (TG), LDL and very low density lipoprotein (VLDL) and significantly ($p<0.05$) elevated the level of HDL in parasitized treated mice. The results suggest that the plant may possess hypolipidemic potential may be due to its antiplasmodial (Olorunnisola and Afolayan, 2011) effect which leads to reduction in parasite density and free radical generation.

Haematological alterations manifested as decreased RBC count, Hb level, PCV, and mean haemoglobin concentration levels as observed in

infected mice in this study are some common signs of anaemia (Surve *et al.,* 2017). During malaria infection, *Plasmodium* parasites invade the host cells and causes destruction of RBC through its metabolic processes (Buffet *et al.,* 2010; Saganuwan *et al.,* 2011). The treatment of animals with the leaf extract and fractions significantly improved the haematological parameters, portraying the leaf extract and fractions capabilities to inhibit parasites growth and development as confirmed by the decreases in parasitaemia. The anti-anaemia activity of plant extract could have been exerted by promoting the regeneration of tissues, decreasing the permeability of blood capillaries or increasing the resistance of cells to haemolysis (Bruneton,2009), which results from the activities of flavonoids known to improve the resistance of erythrocytes to the haemolysis induced by *Plasmodium* (Gbenou *et al*., 2006). Phenolic compounds protect against oxidative damage in RBCs, by preventing lipid peroxidation (Khalili *et al.*, 2014). Significant increases in WBC count observed in this study in infected mice as reported previously in malaria infection (Guyton, 2007), can be attributable to immunogenic response to the parasite and malaria pigment (hemozoin) (Malaguarnera *et al.*, 2002). However, reduced parasitemia associated with the extract/fractions treatment correspondingly caused reduction of leucocytes. Similarly, the platelets counts of the treated infected mice were found to be significantly increased compared to untreated *P. berghei*-infected animals. The extract/fractions treatment of infected mice must have stimulated the immune system thereby offering some degree of protection to the infected mice. This suggests the immunomodulatory activities of some phytochemical constituents of the leaf extract and fractions (Bero and Quertin-Leclercg, 2009).

Conclusion

The results of this study show that the leaf extract and fractions of *Saccharum officinarum* possess antioxidative stress and liver protective potentials which maybe attributed to the activities of its phytochemical constituents.

Acknowledgements

The authors are grateful to Mr. Nsikan Malachy of Pharmacology and Toxicology Department and Mr Adewale Wole of Anatomy Department for providing technical assistance.

References

Adil, R., Sumit, K., Varshney, M., Shahid, M.K. Haris, M., Ashraf Malik, A., Abbas, F.S. and Mahdi, A. (2013). Lipid peroxidation in cerebral malaria and role of antioxidants, *IOSR-PHR*, 3(1): 15-18.

Akwetey GA, Achel DG.(2010).Ethnopharmacological use of herbal remedies for the treatment of malaria in the Dangme West District of Ghana. *J. Ethnopharm*. 129 (3): 367-376.

Asagba, S.O., Eriyamremu, G.E., George, B.O. and Okoro, I. (2010). Biochemical indices of severity in

human malaria. *J Med Sci*, 10(4): 87-92.

Attioua B, Lagnikab L, Yeoc D, Antheaumed C, Kaisere M, Wenigerf B, Lobsteinf A, Vonthron-S_en_echeauf C. (2011). In vitro antiplasmodial and antileishmanial activities of flavonoids from *Anogeissus leiocarpus* (Combretaceae). *Int J Pharmaceut Rev Res*. 11:1–6.

Attioua B, Weniger B, Chabert P. (2007). Antiplasmodial activity of constituents isolated from *Croton lobatus*. *Pharm Biol.* 45:263–266.

Becker K, Tilley L, Vennerstrom JL, Roberts D, Rogerson S, Ginsburg H (2004) Oxidative stress in malaria parasite-infected erythrocytes: Host-parasite interactions. *Int J Parasitol* 34: 163–189..

Bero J, Quetin-Leclercq J. (2011) Natural products published in 2009 from plants traditionally used to treat malaria. *Planta Med* 77(06): 631- 640.

Bruneton J. (2009). Pharmacognosy, phytochemistry, medicinal plants. 4th edition.Tech & documentation and International medical editions: Lavoisier,Paris, p. 1118.

Buffet PA, Safeukui I, Deplaine G, Brousse V, Prendki V, Thellier M,(2010). The pathogenesis of *Plasmodium falciparum* malaria in humans: Insights from splenic physiology. *Blood* 4: 202911.

Casals-Pascual C, Kai O, Newton CRJC, Peshu N, Roberts DJ (2006). Thrombocytopenia in falciparum malaria is associated with high concentrations of IL-10. *Am J Trop Med Hyg* 75(3): 434-436.

Coutinho ID,Baker JM, Ward JL, Beale MH, Creste S,Cavalheiro AJ. (2016). Metabolite profiling of sugarcane genotypes and identification of flavonoid glycosides and phenolic acids *J. Agric. Food Chem.*2016, 64, 21, 4198–4206.

Das BS, Thurnham DI and Das DB (1996). Plasma *a*tocopherol, retinol, and carotenoids in children with falciparum malaria. *Am. J. Clin. Nutr*., 64: 94-100.

Davis TME, Sturm M, Zhang YR, Spencer JL, Graham RM, Li GQ and Taylor RR (1993). Platelet-activating factor and lipid metabolism in acute malaria. *J. Infect.* 26: 279-285.

Ellman GL. (1959). Tissue sulfhydryl groups. *Arch Biochem Biophys*. 82: 70-77.

Esterbauer H, Cheeseman KH. (1990). Determination of aldehydic lipid peroxidation products: malonaldehyde and 4-hydroxynonenal. *Methods Enzymol.* 186: 407–421.

Ezenyi IC, Salawu OA, Kulkarni R, Emeje M. (2014). Antiplasmodialactivityaidedisolation and identification of quercetin-40-methyl ether in *Chromolaena odorata*

leaf fraction with high activity against chloroquine-resistant *Plasmodium falciparum*. *Parasitol Res*. 113:4415–4422.

Fabbri, C., de Cássia Mascarenhas-Netto, R., Lalwani, P., Melo, G.C., Magalhães, B.M., Alexandre, M.A., Lacerda, M.V. and Lima, E.S. (2013). Lipid peroxidation and antioxidant enzymes activity in *Plasmodium vivax* malaria patients evolving with cholestatic jaundice. *Malaria J,* 12: 315.

Ganesh D, Fuehrer H, Starzengruber P, Swoboda P, Khan WA, Reismann JA, Mueller MS, Chiba P, Noedl H. (2012). Antiplasmodial activity of flavonol quercetin and its analogues in *Plasmodium falciparum*: evidence from clinical isolates in Bangladesh and standardized parasite clones. *Parasitol Res*. 110:2289–2295.

George BO, Osioma E, Okpoghono J1 and Aina OO (2011). Changes in liver and serum transaminases and alkaline phosphatase enzyme activities in *Plasmodium berghei* infected mice treated with aqueous extract of *Aframomum sceptrum. Afr. J. of Biochem. Res*., 5(9): 277-281.

Guha, M., Kumar, S., Choubey, V., Maity, P. and Bandyopadhya, U. (2006). Apoptosis in liver during malaria: Role of oxidative stress and implication of mitochondrial pathway. *Federation of American Societies for Experimental Biology Journal*, 20(8): 439-449.

Guthrow CE, Morris JF and Day JW (2007). Enhanced non-enzymatic glycosylation of human serum albumin. *Quart. T. Med*., pp. 30-38.

Guthrow CE, Morris MA, Day JF, Thorpe SR, Baynes JW.(1979). Enhanced nonenzymatic glucosylation of human serum albumin in diabetes mellitus. *Proc Natl Acad Sci* U S A 76(9): 4258-4261.

Guyton A, Hall J. (2007).Textook of medical physiology. 12th ed. Philadelphia.

Hartwell, J.L. 1967–1971. Plants used against cancer. A survey. *Lloydia* 30–34.

Khalili M, Ebrahimzadeh MA, Safdari Y. (2014). Antihaemolytic activity of thirty herbal extracts in mouse red blood cells. *Arch Ind Hyg Toxicol* 65(4): 399-406.

Khan SL, Siddiqui FA. (2020). Beta-Sitosterol: As Immunostimulant, Antioxidant and Inhibitor of SARS-CoV-2 Spike Glycoprotein. *Arch Pharmacol Ther.* 2(1):12-16.

Knight DJ, Peters W. (1980). The antimalarial activity of N-benzyloxydihydrotriazines. I. The activity of clociguanil (BRL 50216) against rodent malaria, and studies on its mode of action. *Ann Trop Med Parasitol.* 74:393–404.

Kohno Y, Egawa Y, Itoh S, Nagaoka S, Takahashi M, Mukai K. (1995). Kinetic study of quenching reaction of singlet oxygen and scavenging reaction of free radical by squalene in n-butanol. *Biochim Biophys Acta.* 1256:52–56.

Kumaradevan G, Damodaran R, Mani P, Dineshkumar G, Jayaseelan T. (2015). Phytochemical screening and GC–MS analysis of bioactive components of ethanol leaves extract of *Clerodendrum phlomidis* (L.). *Am J Biol Pharm Res.* 2:142–148.

Lawrence RA, Burk RF. (1976). Glutathione peroxidase activity in selenium- deficient rat liver. *Biochem Biophys Res Comm* 71: 952-958.

Li WW, Barz W. (2005). Biotechnological production of two new 8,4 '-oxynorneolignans by elicitation of *Echinacea purpurea* cell cultures. *Tetrahedron Letters*, 46(17): 2973-2977.

Malaguarnera L, Musumeci S. (2002).The immune response to *Plasmodium falciparum* malaria. *Lancet Infect Dis* 2(8): 472478.

Marklund S, Marklund G. (1974). Involvement of superoxide anion radical in the autooxidation of pyrogallol and a convenient assay for superoxide dismutase. *Eur J Biochem*, 47: 469 - 474.

Melariri P, Campbell W, Etusim P, Smith P. (2011). Antiplasmodial properties and bioassay-guided fractionation of ethyl acetate extracts from *Carica papaya* leaves. J Parasitol Res. doi: 10.1155/2011/10495.

Melariri P, Campbell W, Etusim P, Smith P. (2012). In vitro and in vivo antimalarial activity of linolenic and linoleic acids and their methyl esters. *Adv Stud Biol.* 4:333–349.

Memon RA, Staprans I, Noor M, Holleran WM, Uchida Y, Moser AH, Feingold KR and Grunfeld C (2000). Infection and inflammation induce LDL oxidation *in vivo*. *Arterioscler ThrombVasc Biol*., 20: 1536-1542.

Nathawut S, Paveena Y, Srivicha K, Wattana L, Gary B, Sornchai L and Rachane U (2004). Increased fluidity and oxidation of malarial lipoproteins: Relation with severity and induction of endothelial expression of adhesion molecules. *Lipids in Health and Dis*, 3: 15.

Obidike IC, AmoduB, EmejeMO. (2015). Antimalarial properties of SAABMAL®: an ethnomedicinal polyherbal formulation for the treatment of uncomplicated malaria infection in the tropics.*Indian J Med Res.* 141(2): 221–227.

Ojewunmi O, Oshodi T, Ogundele O, Micah C,Adenekan S.(2013). Evaluation of the anti-diabetic and antioxidant activities of aqueous extracts of *Morinda lucida* and *Saccharum officinarum* leaves in alloxan-induced diabetic rats. *Intl J.*

Biochemistry Res Review, 3(3): 266-277.

Ojezele, M.O., Moke, E.G. and Onyesom, I. (2017). Impact of generic antimalarial or *Phyllanthus amarus* and vitamin co-administration on antioxidant status of experimental mice infested with *Plasmodium berghei*. *Beni-Suef University J Basic Appl Sci*, 6(3): 260-265.

Okokon JE, Davies K, Edem UA, Bassey AL, Udobang JA.(2021). Analgesic activity of ethanol leaf extract of *Saccharum officinarum.Trop J Nat Prod Res.* 5(6):1142-1145.

Okokon JE, Udoh AE, Nyong EE, Eno L, Udo NM.(2019). Psychopharmacological studies on leaf extract of *Saccharum officinarum*. *Trop J Nat Prod Res.* 3(2):26-30.

Okokon JE, Mobley R, Edem UA, Bassey AL, Fadayomi I, Horrocks P, Drijfhout F, Li WW. (2022). In vitro and in vivo antimalarial activities and chemical profiling of sugarcane leaves. *Science Reports* 41598 Article No:14391 doi. org/ 10. 1038/ s41598 -022-14391-8

Olorunnisola OS, Afolayan AJ (2011). *In vivo* antimalaria activity of methanolic leaf and root extracts of *Sphenocentrum jollyanum* Pierre. *Afr. J. of Pharm and Pharm.,* **5**(14): 1669-1673.

Onyesom I, Onyemakonor N. (2011). Levels of parasitaemia and changes in some liver enzymes among malarial infected patients in Edo-Delta Region of Nigeria. *Curr Res J Biol Sci* 3(2): 78-81.

Orhue, NEJ, Nwanze EAC Okafor A (2005). Serum total protein, albumin and globulin levels in Trypanosoma brucei-infected rabbits: Effect of orally administered Scoparia dulcis. *Afri. J. of Biotechnol.,* 4(10): 1152-1155.

Palaksha MN, Ravishankar K and Girijasastry V. (2013). Phytochemical screening and evaluation of in-vitro antibacterial and anthelmintic activities of *Saccharum officinarum* leaf extracts. *World J Pharmacy and Pharmaceutical Sci*, 2(6):5761-5768.

Palaksha, M. N., Ravishankar, K., GirijaSastry, V. (2015). Biological evaluation of in vivo diuretic, and antiurolithiatic activities of ethanolic leaf extract of *Saccharum officinarum*. *Indo Amer J Pharm Res*. 5(06): 2232-2238.

Ponnamma SU, Manjunath K. (2012). GC-MS analysis of phytocomponents in the methanolic extract of *Justicia wyaadensis*(NEES) T. Anders. Int J Pharma Bio Sci 3:570-576.

Percário S, Moreira DR, Gomes BAQ, Ferreira MES, Gonçalves ACM, Laurindo PSOC, (2012). Oxidative stress in malaria. *Int J Mol Sci* 13(12): 16346-16372.

Peters W. (1965). Drug resistance in *Plasmodium berghei* Vincke and Lips, 1948. I. Chloroquine resistance. *Exp Parasitol.* 17:80–89.

Peters, W., Robinson, B.L. The chemotherapy of rodent malaria. Studies on pyronaridine and other Mannich base antimalarials. *Ann. Trop. Med. Parasitol.* 1992, *86*, 455–465.

Ponnamma SU, Manjunath K. (2012). GC-MS analysis of phytocomponents in the methanolic extract of *Justicia wyaadensis* (NEES) T. Anders. *Int J Pharma Bio Sci* 3:570-576.

Saganuwan S, Onyeyili P, Ameh E, Etuk U. (2011). In vivo antiplasmodial activity by aqueous extract of Abrus. *Rev Latinoamer Quím*. 39(1-2): 32-44.

Sarr, D., Cooper, C.A., Bracken, T.C., Martinez-Uribe, O., Nagy, T. and Moore, J.M. (2017). Oxidative stress: A potential therapeutic target in placental malaria. *Immuno Horizon*, 1(4): 29-41.

Singh A, Lal UR,Mukhtar HM, Singh PS, Shah G, Dhawan RK.(2015). Phytochemical profile of sugarcane and its potential health aspects.*Pharmacogn Rev*. 9(17): 45–54.

Sinha AK. (1972). Colorimetric assay of catalase. *Analytical Biochem*, 47: 389 - 94.

Surve K, Kulkarni A, Rathod S, Bindu R. (2017). Study of haematological parameters in malaria. *Int J Res Med Sci* 5(6): 2552-2557.

Sun J, He X, Zhao M, Li L, Li C, Dong Y. (2014). Antioxidant and nitrite-scavenging capacities of phenolic compounds from sugarcane (*Saccharum officinarum* L.) tops *Molecules* 19: 13147-13160.

Tietz, W. W. (1990). *Clinical Guide to Laboratory tests.* 2nd edn. Sanders Company. Philadelphia, PA. pp. 554-556.

Trager W, Jensen JB. (1976). Human malaria parasites in continuous culture. *Science*. 193:673–675.

Udobang J, Okokon JE, Bassey AL (2017). antimalarial and antipyretic activities of ethanol extract and fractions of *Setaria megaphylla* root. *Journal of Coastal life Medicine*. 5(7): 309 - 316.

World Health Organisation (2020). World Malaria reports.www. who. Int/publications /m/item/WHO-HTM-GMP-2020.08