A safety profile of aqueous methanol aerial extract of *Alysicarpus glumaceus* in mice: acute and subacute administration

Ferhat Khan[1], Munir Ari Sani[2], Amina Busola Olorunkooba[1], Saratu N Danraka[1], Mohammed Garba Magaji[1], Ibrahim Abdu-Aguye[1], Isa Marte Hussaini[3],

[1]Department of Pharmacology and therapeutics, Ahmadu Bello University, Zaria-Nigeria
[2]Department of Veterinary Surgery and Radiology, Ahmadu Bello University, Zaria-Nigeria
[3]Department of Pharmacology, University of Maiduguri, Maiduguri-Nigeria
Submitted: 6th June, 2022; Accepted: 23rd June, 2022; Published online: 3oth June, 2022
DOI: *https://doi.org10.54117/jcbr.v2i3.18*

Corresponding author: Ferhat Khan Phone: +2348033469257 fkhan@abu.edu.ng; khanferhat@ymail.com

Abstract

Alysicarpus glumaceus (Vahl D.C), family-leguminosae is used traditionally for a number of ailments in Nigeria, as well as in other African countries, Asia and middle east. The leaf is taken orally for thrush, sores and asthma. While root decoction is taken for coughs and its combination with leaf sap is taken for diarrhea and as an abortifacient. The aerial parts are used for the management of neuropsychiatric disorders mainly depression and currently been used by drivers in combination with tea to keep alert on long drive in northern Nigeria. The aim of this work was to determine the median lethal dose (LD_{50}) and the effect of aqueous methanol extract (AME) of *Alysicarpus glumaceus* on the body weight, behavioural changes, heamatological, histopathological parameters and rate of mortality after an acute and sub-acute toxicity study of 28 days using three graded doses (500, 1000 & 1500 mg/kg) in mice via the oral route. From the results obtained LD_{50} was greater than 5000 mg/kg, it had no significant effect on their body weights as well as on their physical behaviour. Slight lesions were observed in kidney and liver of animals given 1500 mg/kg of AME. There was no statistical difference ($p< 0.05$) between the control and the treated groups for packed cell volume and platelet count. These findings suggest that the AME of *Alysicarpus glumaceus* is not likely to produce toxic effects and suggest that the extract is relatively safe in mice.

Keywords: *Alysicarpus glumaceus*, acute, sub-acute and Toxicity

Introduction

About three quarters of the world population living in developing countries have been estimated by World Health Organization (WHO) to rely upon folkloric remedies (mainly medicinal plants-MP) as one of the surest means to achieving total health coverage for its people (Gilani & Atta-ur-Rahman, 2005; Ouédraogo et al., 2007; Antwi-Baffour, 2014; Kakooza-Mwesige, 2015; Mensah et al., 2019). There is also an increase in the use of these folkloric remedies in the developed countries (Msomi & Simelane, 2018). The worldwide annual market for these products from medicinal plants was US$ 60 billion in 2002 (W. H. O, 2002) and reached US$110.2 Billion in 2020, while it is projected to reach US$178.4 billion by 2026 (ReportLinkers, 2022). That is the reason why WHO is encouraging the preservation and standardization such preparations. In Africa, these plants constitute a part of the cultural heritage and play an important role in the daily life of many people (Bisi-Johnson et al., 2010) as they contribute to the strategies for reducing the burden of illnesses and death

due to diseases. Over 4500 species of MP exist in Nigeria, making it the 11th Country in Africa for diversity (Vasisht & Kumar, 2004). One of such medicinal plants used in Nigeria is ***Alysicarp*us *glumaceus* (Vahl) DC**, though not only indigenous to west Africa also commonly found in Kenya, Djibouti, Ethiopia, Sudan, Swaziland, Tanzania, Rwanda; as well as in India and Yemen (Burkill, 1985).

*Alysicarp*us *glumaceus* is commonly known as Alyce clover, alysicarpus, buffalo clover etc. *A. glumaceus* is very similar to its other species *Alysicarpus rugosus* or *Alysicarpus ovalifolius* during the vegetative stages, thus difficult to identify (CIRAD, 2010). *A. glumaceus* belongs to the family leguminosae. A shrubby, loosely branched, creeping and ascending non-climbing annual to 1 m high of the grassy savanna mostly found in Northern Nigeria, where it is locally known as gadagi in hausa and bundiya in Fulani.

It has been reported that *A. glumaceus* has phytoconstitutents like cardiac glycosides, steroids, triterpenes, saponins, flavonoids, alkaloids, tannins. The isolation of two glycosidic flavonones from *n*-butanol fraction of its methanol extract has also been reported (Bawa, et al, 2012 ; Khan et al., 2021).

The aerial parts of *A. glumaceus* are used for neuropsychiatric diseases especially depression (personal communication), the concoction of the leaves and roots are reportedly used as antimotility agents while the roots are used for the treatment of gout and oedema, as an abortifacient and as an antidote for snake bites. The leaf is generally used for wound healing (local application on old wounds, burns and leprosy), treatment of respiratory diseases (nasopharyngeal infections, cough, and asthma) and stomach aches (Vasisht & Kumar, 2004; Bekalo et al., 2009; Pandya, 2009; Dukku, 2017;). A poly herbal preparation (gadagi tea) with *Alysicarpus ovalifolius* as the main ingredient has been used in Kano State-Nigeria for over fifty years as an herbal stimulant and energy drink. (Dukku, 2017; Khan et al., 2021). In another research, by Olorukooba et al., (2019), methanol aerial extract of *A.glumaceus* has been reported to have antiplasmodial activity.

Despite long record of medicinal usage of *A. glumaceus*, there is dearth of information on its safety or toxicity profile. The purpose of the study is to evaluate the acute and subacute oral safety profile of the aqueous methanol extract (AME) of *A. glumaceus*.

Materials and methods

Plant collection

The whole plant of *A. glumaceus* was collected from Turunku, Igabi Local Government Area, Kaduna State-Nigeria in the month of September, authenticated at the Department of Biological Sciences, Ahmadu Bello University, Zaria-Nigeria, a voucher specimen number (446) was obtained and deposited for future reference.

Plant extraction

Three kilogram of 20 days shade dried coarse aerial parts of *A. glumaceus* obtained after being size reduced in the pestle and mortar were used and macerated (70:30; methanol:water) for 10 days with occasional shaking. The menstruum was collected, filtered and allowed to concentrate by air drying at room temperature. The concentrated filterate was referred to as aqueous methanol extract (AME). The AME was successively partitioned into n-hexane, ethyl acetate, chloroform and n-butanol. These were subsequently concentrated as n-hexane (HEX), ethyl acetate (EAF), chloroform (CCF), n-butanol (BUT) and residual aqueous fraction (RAF). The AME and its fractions were preserved in a desiccator until use for further studies.

Animals

Young adult albino Swiss mice (18–22 g) of either sex were obtained from the Animal house facility of Department of Pharmacology and Therapeutics, Ahmadu Bello University, Zaria-Nigeria and they were randomly distributed into different experimental groups. The animals were housed in standard polypropylene cages with uniform conditions of lighting at room temperature and fed on standard mouse feed and water *ad libitum.* An approval was obtained for the experimental protocols from the Ahmadu Bello University Committee on Animal Use and Care (ABUCAUC) with approval number ABUCAUC/2018/076.

Chemicals and Equipment

Chloroform (Sigma-Aldrich Chemicals), Formaldehyde (Fluka), Xylene (BDH Ltd Poole, England), EDTA bottles, haematocrit tube, microhaematocrit centrifuge reader (Hawskley model no 1675), Beckman Coulter, colorimeter (Optima, Japan, model no AC 116), counting chamber for leukocyte count (Hawskley, model 0278), Metler weighing balance p165,

Acute toxicity test

The acute toxicity (LD_{50}) was estimated orally in mice using Lorke's method (1983) (Lorke, 1983). Dose of 10, 100, and 1000 mg/kg were used for the first phase. The number of deaths in each group within 24 hours was recorded. In the second phase which was deduced from the first phase, four mice were grouped into three groups of one mouse each and they were treated with doses of 1600, 2900, and 5000 mg/kg orally. They were also observed for 24 hours as in the first phase, and final LD_{50} value was determined from Lorke's formula as follows: $LD_{50} = \sqrt{a \times b}$, where a is the highest dose at which no death occurred in the second phase and b is the least dosage at which death occurred in the 2nd phase. The extract was classified using the LD_{50}.

Sub-acute toxicity test

The study was conducted in compliance with Organisation for Economic Co-operation and Development (OECD) guidelines No. 407 (OECD, 2008). The first group served as control, while the remaining three groups were given 500, 1000 and 1500 mg/kg of AME of *A. glumaceus* orally for 28 days. The first day of dosing was considered as D_0, whereas the last day was designated as D_{29}. On D_{29}, the mice were fasted overnight before they were humanely euthanized by exsanguinations under chloroform anaesthesia. The brain, heart, liver, kidney, spleen and the gonads were dissected, cleansed of adhering tissues, rinsed in normal saline before their weights were measured and put in liquid paraffin for histopathological analysis while the blood was used for heamatological analysis. The values obtained for the control group were considered as the reference values; and statistical analysis was conducted against the control group.

Behavioural, physical signs and mortality rate.

All the animals were individually observed on daily basis for 28 days for likely behavioural, physical signs and mortality rate for up to 4 hours after the daily treatment. Specific attention was paid on changes in body weight, fur, eyes, tremors and convulsions.

Determination of hematological parameters

Determination of haematological parameters such as red blood cell (RBC) count, haemoglobin (Hb), packed cell volume (PCV), mean corpuscular volume (MCV), mean corpuscular haemoglobin (MCH), mean corpuscular haemoglobin concentration (MCHC), platelet (PLT),

white blood cells (WBC) and WBC count were carried out using Beckman Coulter (Beckman Coulter Inc., CA, USA).

Determination of Packed Cell Volume (PCV)

The haematocrit tube was filled with adequately with anticoagulant treated blood before sealing one end of the tube with clay. The tube was then placed and spun for 5 minutes in the microhaematocrit centrifuge (hawskley model no 1675), the PCV was read using the microhaematocrit centrifuge reader.

Determination of heamoglobin (Hb)

Haemoglobin was determined using the haemiglobincyanide (hicn) method. One part of whole blood was diluted drabkins solution to make 1:20 solution. The red blood cells (RBC) were heamolyzed and the Hbwas oxidized by the ferricyanide to metheamoglobin which was then converted by the cyanide to stable haemiglobincyanide. Absorbance of the hicn solution was read at 540nm using a colorimeter (optima, japan, model no AC 116). The absorbance obtained was compared to that of a standard hicn solution.

Determination of total white blood cell (WBC), total RBC and PLT

The total WBC, RBC and PLT counts were determined by diluting the blood with the appropriate diluting fluids (1 in 20 for WBC, 1 in 100 for RBC and 1 in 20 for PLT). The diluted blood was then placed in a mounted counting chamber (hawskley, model 0278). The WBC and PLT were counted from the large squares of the counting chamber while the RBCs were counted from the small squares.

Differential white blood cell counts

A drop of blood was placed on one end of the slide with the aid of a spreader a thin blood film was made. The blood film was then stained using Leishman stain and dried. The dry stained blood film was examined under a microscope using the oil immersion objective (x100). The number of neutrophils, lymphocyte, monocyte, basophil and eosinophil were noted and recorded from 100 WBC.

Histopathological examination

The brain, heart, liver, kidneys, spleen and the gonads were fixed in 10 % (v/v) formaldehyde, dehydrated through ascending grades of ethanol (70 %, 90 % and 95 % v/v), cleaned in xylene and embedded in paraffin wax. Tissue sections were prepared and stained with hematoxylin/eosin. The photomicrographs were taken at ×400 using the standard light microscope (Ashafa et al., 2012; Gandhare et al., 2013).

Statistical Analyses

Results obtained were analyzed using One-Way Analysis of Variance (ANOVA) followed by Bonferroni post-hoc test. Data obtained for the weight was analyzed using Repeated Measures ANOVA followed by Bonferoni post-hoc test. Data were presented as tables, figures or plates where necessary. Results were considered significant at $p>0.05$.

Results

Acute Toxicity Studies

Median Lethal Dose (LD_{50}) Values of Aqueous Methanol Extract of *Alysicarpus glumaceus* and its Fractions

The Aqueous methanol extract of *A. glumaceus* and its fractions had their estimated LD_{50} to be greater than 5000 mg/kg in mice using the Lockes' method of 1983 (Table 1).

Table 1: Median Lethal Dose (LD_{50}) Values of Aqueous Methanol Extract of *Alysicarpus glumaceus* and its Fractions

Groups	LD_{50} values
1. AME	>5000 mg/kg
2. **HEF**	>5000 mg/kg
3. **EAF**	>5000 mg/kg
4. **CCF**	>5000 mg/kg
5. **NBF**	>5000 mg/kg
6. **RAF**	>5000 mg/kg

AME- Aqueous Methanol Extract, **HEF**- Hexane Fraction, **EAF**- Ethyl acetate fraction, **CCF**-Chloroform fraction, **NBF**- n-butanol fraction, **RAF**- Residual aqueous fraction.

Subacute Toxicity Studies of Aqueous Methanol Extract of Alysicarpus glumaceus

Effect of Aqueous Methanol Extract of Alysicarpus glumaceus on General Behaviour and Mortality Following 28 days of Oral Administration in Mice

The treated mice were not any different from the control in relation to the behaviour. Some little changes were noticed in the reflex activities across all the groups as from D_{25}, changes in the fur pattern and slightly greenish stool started to appear on D_{26} in the 1500 mg/kg treated group with AME of *A. glumaceus*. There was no mortality in the group treated with 500 and 1500 mg/kg of AME, though in the group treated with 1000 mg/kg and in the control group, a mouse died in each of the groups on D_{24} and D_{21} respectively.

Table 2: Effect of Aqueous Methanol Extract of *Alysicarpus glumaceus* on General Behaviour and Mortality Following 28 days of Oral Administration in Mice

Treatment (mg/kg)	Mortality	Change in fur pattern	Change in stool pattern	Change in reflex actions
D/W (10 mL/kg)	1/8	0/8	0/8	0/8
AME 500	0/8	0/8	0/8	1/8
AME 1000	1/8	1/8	1/8	1/8
AME 1500	0/8	1/8	2/8	3/8

DW- Distilled Water; AME- Aqueous Methanol Extract (n=8)

Effect of Aqueous Methanol Extract of Alysicarpus glumaceus on Body Weights Following 28 days of Oral Administration in Mice

There was no significant difference (p>0.05) in their body weights in both the treated and control groups as shown by the results in this study as seen in Figure 1.

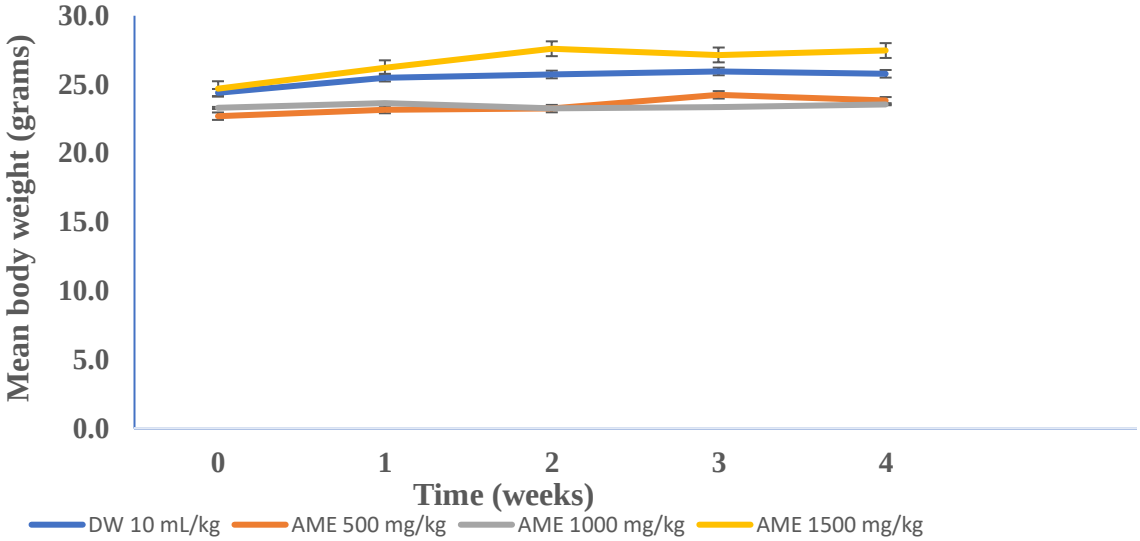

Figure 1:**Effect of Aqueous Methanol Extract of *Alysicarpus glumaceus* on Mean Weights of Mice Following 28 days of Oral Administration**

AME- Methanol Extract

Effect of Aqueous Methanol Extract of Alysicarpus glumaceus on Heamatological Parameters Following 28 days Oral Administration

Slight changes were observed in the levels of heamatological parameters evaluated in all the treated groups. Aqueous Methanol extract of *A. glumaceus* at the dose of 500 mg/kg induced a significant (p>0.05) increase in RBC and decrease in MCH and PCT. However, there was an insignificant increase in PCV, PLT, MCHC and WBC at the same dose. The group that received 1000 mg/kg had a significant (p>0.05) increase and a decrease in MCHC and MCV respectively and a non-significant increase in PLT and WBC. While the mice that received 1500 mg/kg had no significant change in any of the parameters that were evaluated in comparison with the distilled water treated group (Table 3).

Table 3: Effect of Aqueous Methanol Extract of *Alysicarpus glumaceus* on Heamatological Parameters Following 28 days Oral Administration

Parameter	DW (10 ml/kg)	AME 500 mg/kg	AME 1000 mg/kg	AME 1500 mg/kg
RBC	5.92±0.06	7.79±0.35*	5.88±0.44	5.47±0.15
Hb	12.67±.065	13.52±.65	10.12±0.74	12.68±.59
MCV	65.43±3.10	55.63±0.93	50.45±0.64*	69.92±3.53
MCHC	32.73±0.35	33.67±0.27	34.25±0.25*	33.42±.39
MCH	21.43±1.16	17.35±0.24*	20.23±0.19	23.23±1.14
PLT	270.5±0.62	341.5±2.38	319.17±2.39	217.33±0.66
PCT	7.2±0.08	3.1±0.41*	5.92±0.39	6.75±0.11
PCV	37.5±0.07	40.3±2.06	29.68±2.25	38.0±1.9
WBC	3.4±0.5	6.47±1.18	4.3±0.59	2.8±0.43
LYMP	83.33±0.49	78.85±2.68	81.87±2.72	82.67±0.76
GRA	16.67±0.49	13.32±2.54	10.38±1.94	17.33±0.76

Data are presented as mean ± SEM , *=$p<0.05$, compared to distilled water data analysed by one-way ANOVA followed by bonferroni post hoc test (n=8); DW- Distilled Water; AME-Aqueous Methanol Extract); RBC-Number of Red Blood Cells ($x10^6$\µL); Hb-Weight of Haemoglobin (g\dL); MCV-Mean Corpuscular Volume (fl); MCHC-Mean Corpuscular Haemoglobin Concentration (g\dL); MCH-Mean Corpuscular Haemoglobin (pg); PLT-Platelets ($x10^6$\µL); PCT-Volume of Haemotocrit (%); PCV-Packed Cell Volume (%); WBC-White Blood Cells; LYMP-Lymphocytes; GRA-Granulocytes

Effect of Aqueous Methanol Extract of Alysicarpus glumaceus on histology of organs following 28 days oral adminstration.

Across all the treated groups the brain, heart and uterus had normal features, there was no significant pathological changes/degradation detected in brain as shown in Plate III, heart had normal myocardial fibers (Plate IV) and normal endometrium and supporting tissues of the uterus (Plate V). Similarly, examination of histological sections of the testes, kidney, liver and spleen of the mice administered 500 mg/kg, 1000 mg/kg of AME of *A. glumaceus* and 10 mL/kg of distilled water did not reveal inflammatory symptoms, necrosis and apoptosis or hydropic degeneration of cells.

However, the morphology of the testes of two mice out of the four (2/4) that received the highest dose of 1500 mg/kg of AME of *A. glumaceus* had slight necrosis of the spermatogenic cells (Plate IV.D). Similarly, the photomicrograph of sections of the liver showed Kupffer cell hyperplasia in two out of the eight mice (2/8) (Plate V.D), likewise in the photomicrograph of the kidney (Plate VI.D) and spleen (Plate VII.D) both had slight lymphocyte hyperplasia (LH) in three mice (3/8) each as compared to the control group (distilled water - 10 mL/kg).

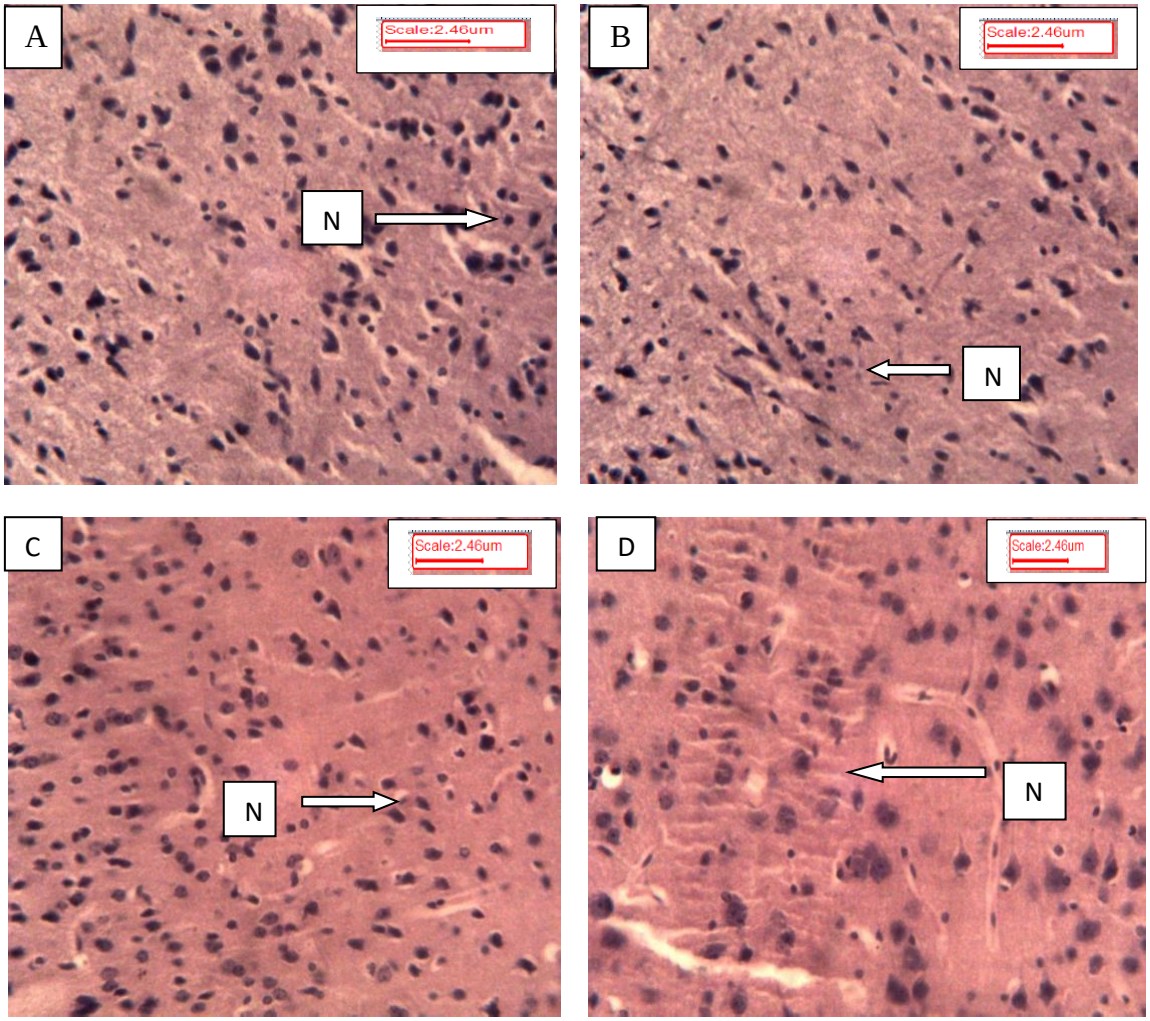

Figure 2: Photomicrograph of Sections of the Mouse Brain Following 28 Days Oral Treatment with Aqueous Methanol Extract of *Alysicarpus glumaceus* (H and E X 400)

A=Distilled Water (10 mL/kg), B=500 mg/kg AME, C=1000 mg/kg AME, D=1500 mg/kg AME. AME-Aqueous Methanol Extract of *Alysicarpus glumaceus.* N-Normal cell

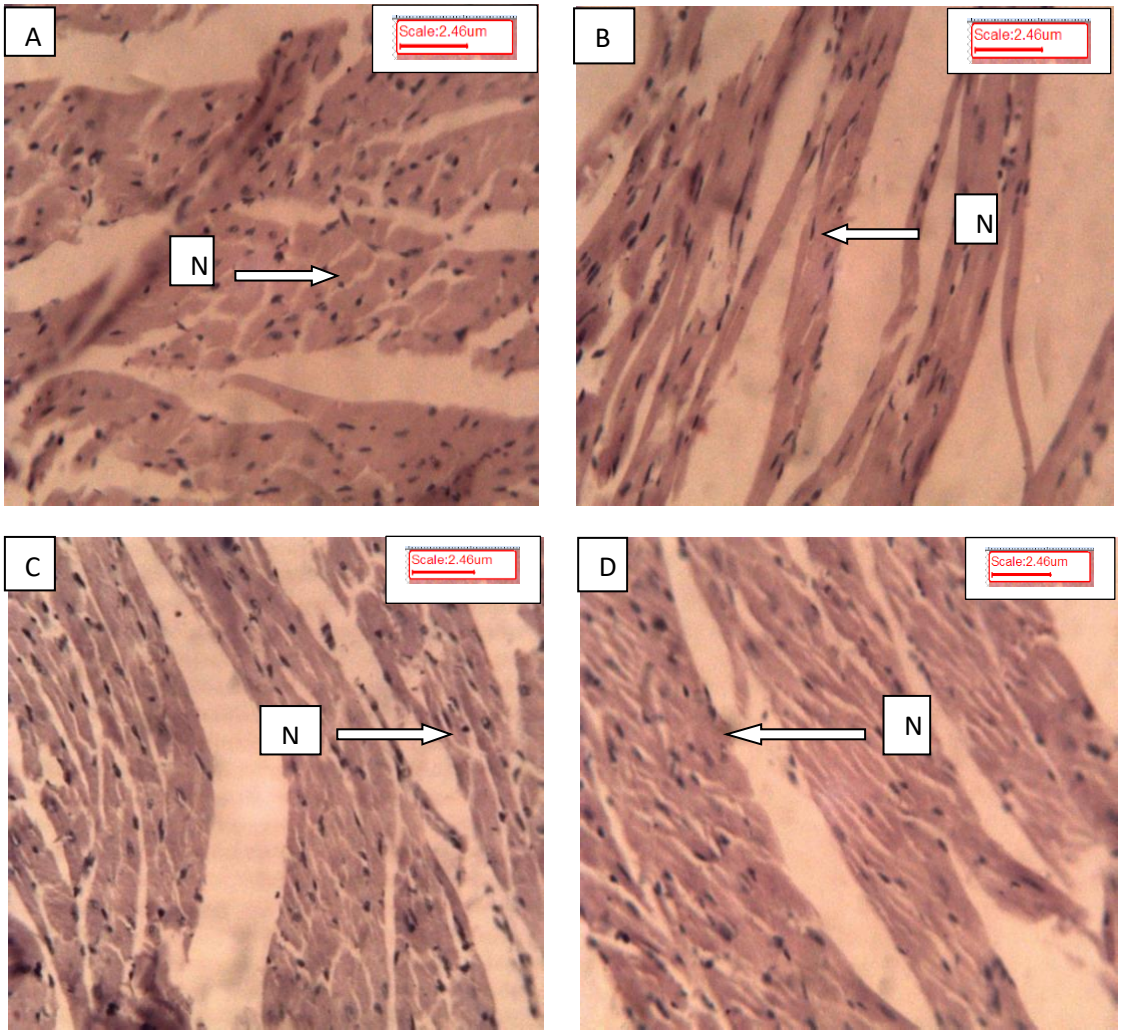

Figure 3: Photomicrograph of Sections of the Mouse Heart Following 28 Days Oral Treatment with Aqueous Methanol Extract of *Alysicarpus glumaceus* (H and E X 400)

A=Distilled Water (10 mL/kg), B=500 mg/kg AME, C=1000 mg/kg AME, D=1500 mg/kg AME. AME-Aqueous Methanol Extract of *Alysicarpus glumaceus*. N-Normal cell

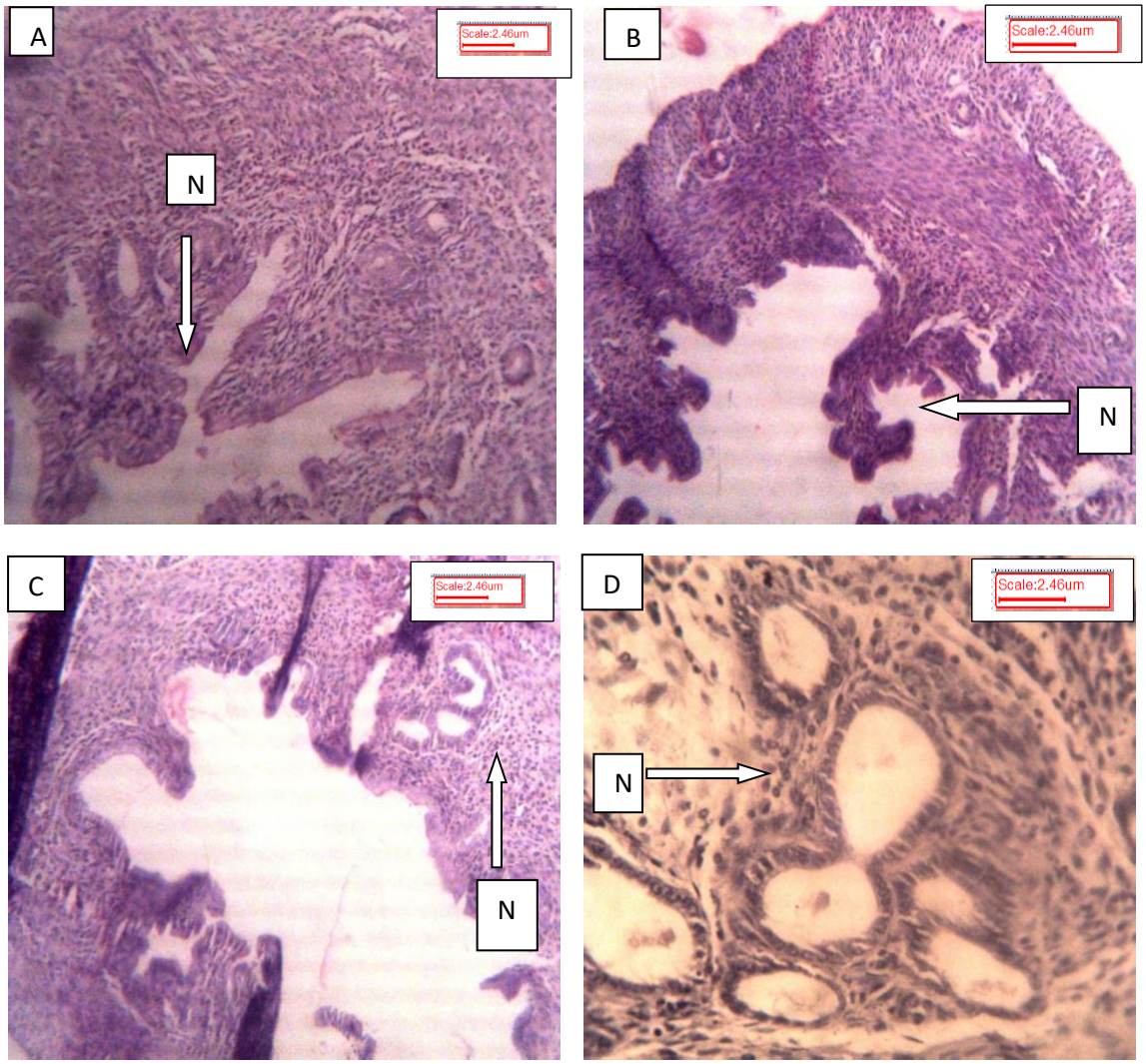

Figure 4: Photomicrograph of Sections of the Mouse Uterus Following 28 Days Oral Treatment with Aqueous Methanol Extract of *Alysicarpus glumaceus* (H and E X 400)

A=Distilled Water (10 mL/kg), B=500 mg/kg AME, C=1000 mg/kg AME, D=1500 mg/kg AME. AME- Aqueous Methanol Extract of *Alysicarpus glumaceus.* N-Normal cell

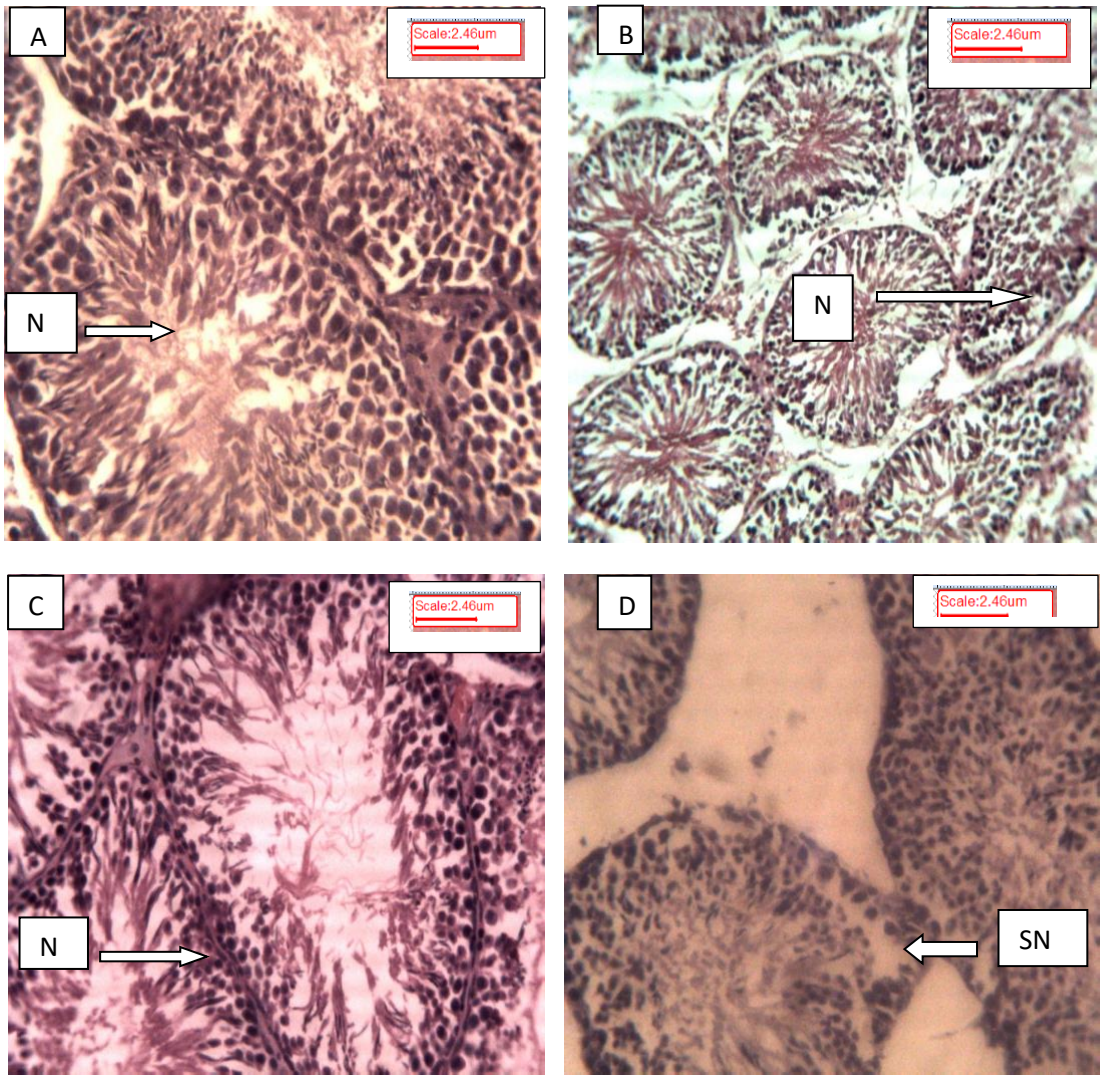

Figure 5: Photomicrograph of Sections of the Mouse Testis Following 28 Days Oral Treatment with Aqueous Methanol Extract of *Alysicarpus glumaceus* (H and E X 400)

A=Distilled Water (10 mL/kg), B=500 mg/kg AME, C=1000 mg/kg AME, D=1500 mg/kg AME (Testis showed slight necrosis (SN) of the spermatogenic cells). AME- Aqueous Methanol Extract of *Alysicarpus glumaceus.* N-Normal cell

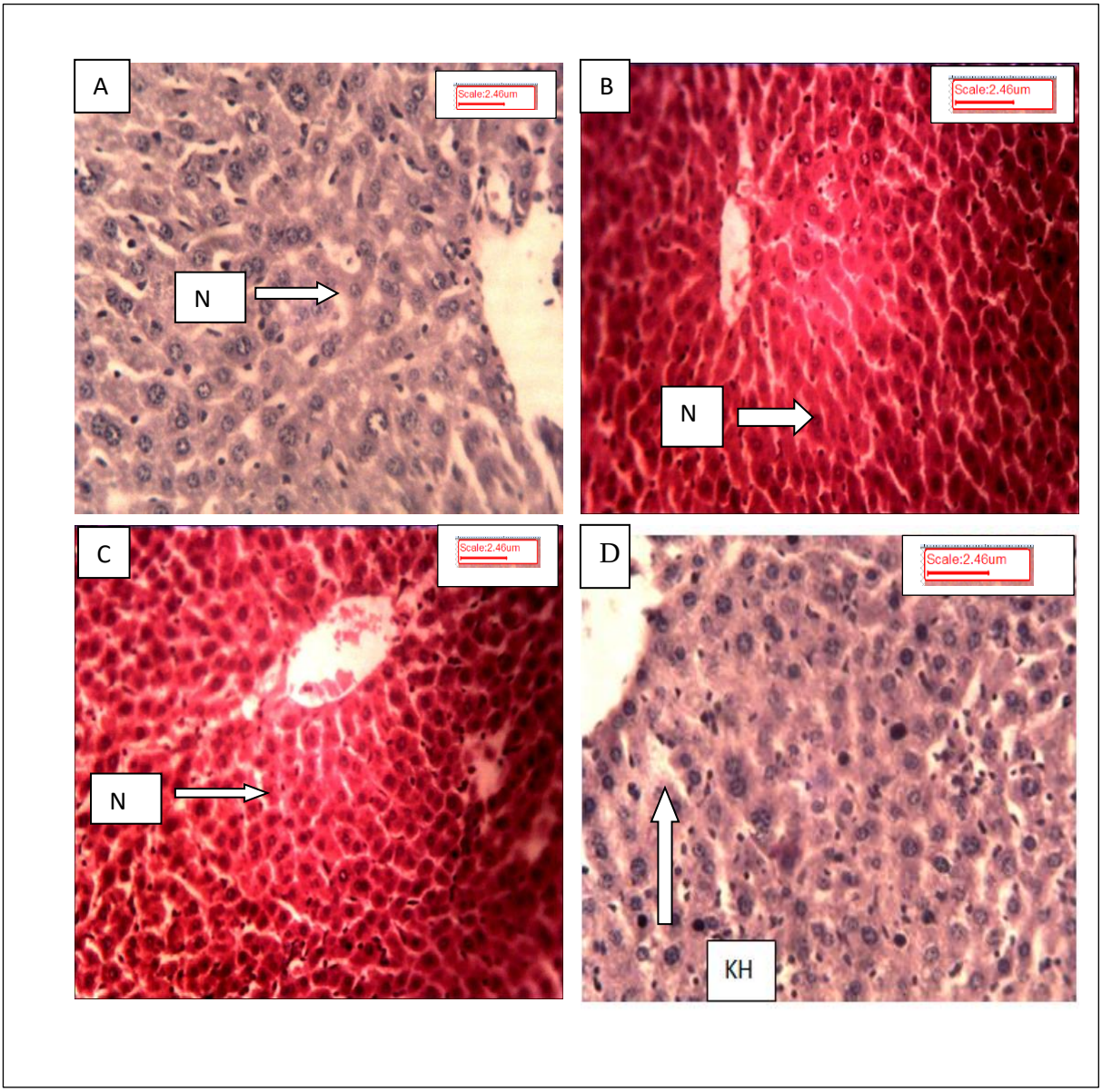

Figure 6: Photomicrograph of Sections of the Mouse liver Following 28 Days Oral Treatment with Aqueous Methanol Extract of *Alysicarpus glumaceus* (H and E X 400)

A=Distilled Water (10 mL/kg), B=500 mg/kg AME, C=1000 mg/kg AME, D=1500 mg/kg AME (Liver showed Kupffer cell Hyperplasia -KH). AME- Aqueous Methanol Extract of *Alysicarpus glumaceus*, N-Normal cell

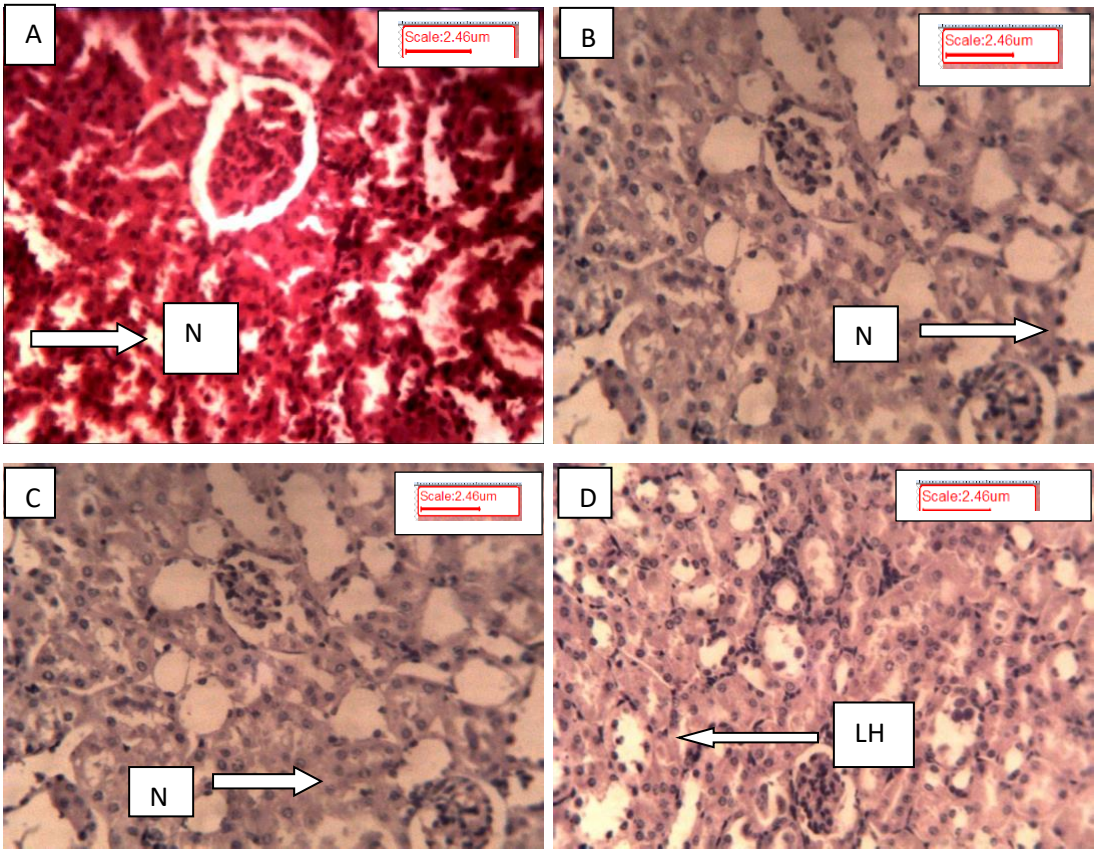

Figure 7: Photomicrograph of Sections of the Mouse Kidney Following 28 Days Oral Treatment with Aqueous Methanol Extract of *Alysicarpus glumaceus* (H and E X 400)

A=Distilled Water (10 mL/kg), B=500 mg/kg AME, C=1000 mg/kg AME, D=1500 mg/kg AME -Kidney showed slight lymphocyte hyperplasia (LH). AME- Aqueous Methanol Extract. N-Normal cell

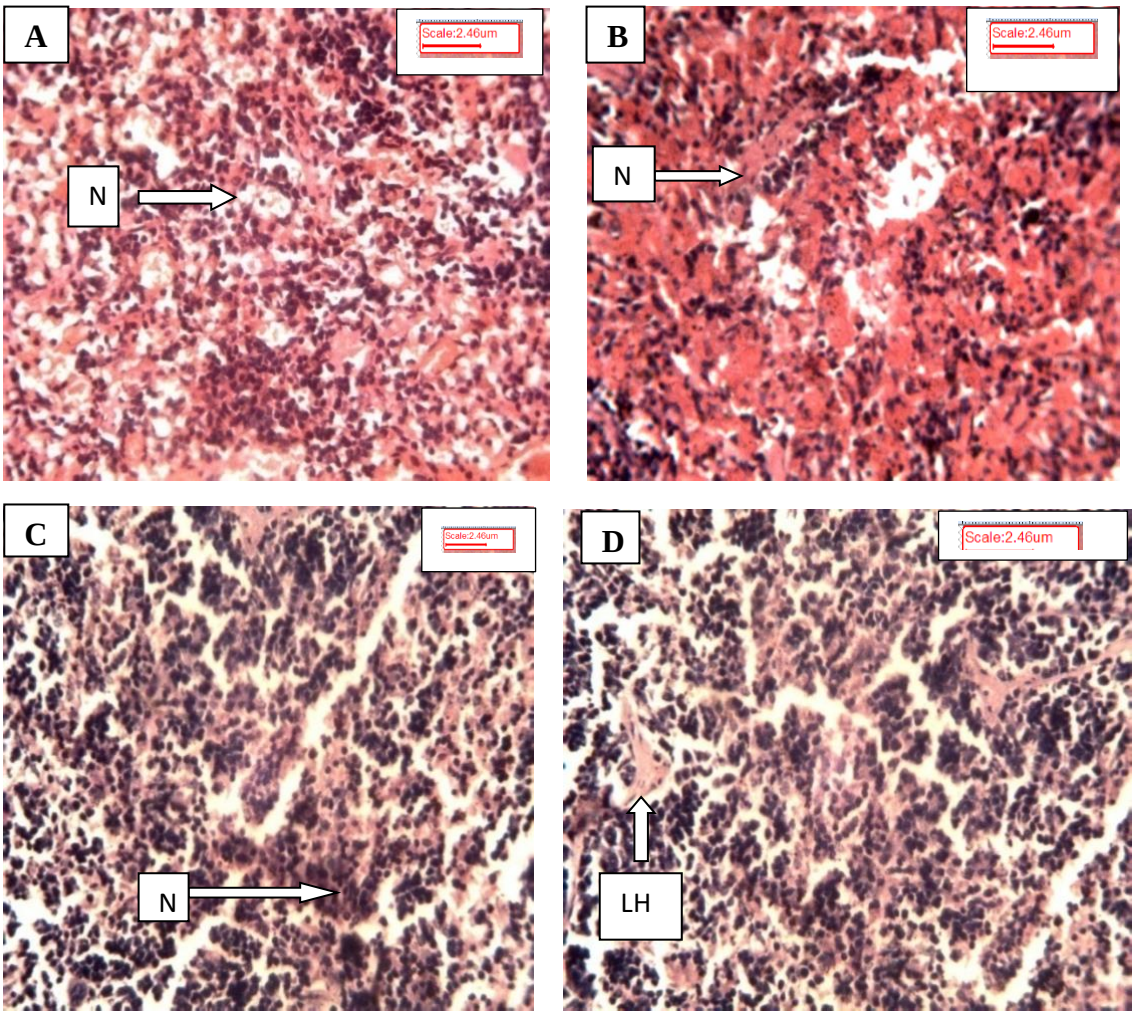

Figure 8: Photomicrograph of Sections of the Mouse Spleen Following 28 Days Oral Treatment with Aqueous Methanol Extract of *Alysicarpus glumaceus* (H and E X 400)

A=Distilled Water (10 mL/kg), B=500 mg/kg AME, C=1000 mg/kg AME, D=1500 mg/kg AME - spleen showed slight lymphocyte hyperplasia (LH). AME- Aqueous Methanol Extract of *Alysicarpus glumaceus.* N-Normal cell

Discussion

Acute toxicity test is a ratio between the lethal dose(LD) and the effective dose(ED) - LD_{50}/ED_{50} (Gandhare et al., 2013), the greater the value the safer the test compound and vice versa (Ghosh & Acharya, 2011). All the test doses used in the study were lower than the 30% of the LD_{50} which was adapted from a study done by (Vongtau et al., 2004). The oral median dose of aqueous methanol extract of *A. glumaceus* and its fractions were estimated to be greater than 5000 mg/kg, hence suggesting that they are safe (Matsumura, 1985; Loomis and Hayes, 1996) or practically non-toxic (Lorke, 1983). This extract being safe may partly be related to the fact that the Fourier-Transform-Infrared (FT-IR) data as reported by Khan (Khan et al., 2021) had no absorbance observed in the region 2220-2260cm^{-1}, indicating that there was no presence of cyanide group, which is a toxicophore (Ragavendran et al, 2011; Abdoun et al., 2019). Although, this finding was in disagreement with Bawa and co-workers (Bawa et al, 2012) that reported the LD_{50} values from methanol extract of *A. glumaceus* and its fractions was less than 5000 mg/kg this disparity could possibly be

due to the time and place of collection of the plant, different methods of extraction and fractionation of the extracts, as well as the percentage of the extractant, methanol left in the extract after drying.

Change in the organ and body weights of animals after exposure to xenobiotics over a period of time is important and can be used as an indicator of adverse effects (Carol, 1995). Some studies have reported that increase in the body weight of animals is more closely related to body fat accumulation rather than the toxic effects of drugs (Harizal et al., 2010). However, in studies by Rhiouani and coworkers (Rhiouani et al., 2008) and (Ouédraogo et al., 2007; Tucci, 2010) reported that body weight loss of animals in toxicity studies or in normal intake may be associated with normal physiological adaptation responses to the plant extract or compounds, which leads to low appetite and lower caloric intake by the animal. No significant changes were observed in body weights of all the treated groups compared to the control group following 28 days of oral administration of methanol extract of *A. glumaceus* in mice. This suggests that there was not much significant alteration in the carbohydrate, protein and fat metabolism (Klaassen, 2013).These results indicate that the appetite of the mice were not affected by the repeated exposure to the extract and the extract had no adverse effects on the growth of the animals.

Mortality is a vital component of toxicological assessment (Asare et al., 2012). There was no mortality from the acute administration of AME of *A. glumaceus* and its fractions, while in the sub-acute toxicity studies there was a death each from the 1000 mg/kg of AME of *A. glumaceus* and the DW treated group. Mortality that occurred was not dose-related, so they were considered as incidental and not treatment-related, implying that mortality may not be due to the toxic effects of the extract.

Haematological parameters are measurable indices of the blood and their assessment gives insight to the extent of effect of xenobiotics on inflammation, necrosis, various infections of visceral organs and the presence of stress factors (Melillo, 2007; Yakubu et al., 2007; Betancourt-Alonso et al., 2011; Jurcik et al., 2013;). These parameters are used to evaluate the hematopoietic function (Obianime et al., 2010), which determine the physiological and pathological status of mammals, as it provides information on the reaction of the body to injury (Mukinda and Eagles, 2010; Abubakar, et al , 2020). The data obtained from heamatological assessment in animals can serve as indicative value for human toxicity once they are extrapolated to humans (Olson et al., 2000).

The aqueous methanol extract of *A. glumaceus* did not produce a significant dose dependent alterations on the haematological parameters assessed except at the dose of 500 mg/kg, which produced a significant (p<0.05) increase on the RBC count (Table 3), and decrease MCH, and also at the dose 1000 mg/kg where significant (p<0.05) increase in MCHC and decrease in MCV were observed. RBC and factors relating to it (Hb, PCV, HGT, MCV, MCH and MCHC) are major indices for evaluating circulatory erythrocytes, they are significant also in the diagnosis of anaemia and serve as useful indices of the bone marrow capacity to produce RBC as in mammals (Peters et al., 2011; Ozkan, 2012; Etim, 2014). This result suggests that *A. glumaceus* at the doses used did not adversely affect erythropoiesis, morphology or osmotic fragility of RBCs. Hence, it may not likely cause anaemia and may also not affect the oxygen carrying ability of the blood.

WBCs and its differentials (platelets, lymphocytes, granulocytes, neutrophils) are the first line of mediators of immunoprotection against invading foreign agents in the body (Aprioku, 2017). Results

showed that WBCs and the differentials obtained in both the treated and control group after 28 days of oral administration were almost similar which suggested that probably AME of *A. glumaceus* did not cause any significant alteration to the immune system of the treated mice. Previous studies have also reported similar findings in their work in rats and mice respectively after subacute administration of herbal extract (Prasanth *et al.,* 2015; Jatsa et al., 2019)

The histology of the mouse brain and heart revealed normal features in the control and extract treated groups respectively, implying no or little toxic effects on these organs. This observation indicated that the aqueous methanol extract of *A. glumaceus* only exerted a mild or insignificant effect on the anatomy of the brain and the heart. And the same can be inferred to the uterus. The testes, however, showed slight necrosis of spermatogenic cells at the dose of 1500 mg/Kg. The testis is highly susceptible to toxicity by chemicals and many medicinal plants have been reported to adversely affect testicular function in animals (Obianime et al., 2010; Aprioku & Obianime, 2014).

Based on the liver's histological results from this study, there was no observable or significant lesion in the groups treated with dose of 500, 1000 mg/kg of the extract. However, 3 mice in at 1500 mg/kg exhibited Kupper cell (KC) hyperplasia, slight foci necrosis and hypertrophy of the nucleus respectively. KCs are phagocytic and ingest substances to provide the first line of defense against invading particles (Chen et al., 2013). Thus, KC hyperplasia and the other slight changes noticed may just be a compensatory mechanism by the hepatocytes in response to the extract administration.

Subacute administration of the extract did not reveal significant alteration in the pathology of both the kidney and spleen tissue except slight lymphocyte hyperplasia, which may signify abnormal proliferation of matured lymphocytes. Lymphocytes are dynamic cells and the second most common WBCs which function primarily to respond to antigens by initiating the immune response (Pearce et al., 2013). The increase in lymphocytes may suggest possible immuno-stimulatory effect of the plant. The changes that occurred did not follow a defined pattern, but were only noticed in mice treated with the highest dose of the extract.

Conclusion

These findings suggest that the aqueous methanol extract of *Alysicarpus glumaceus* is relatively safe in mice following acute and subacute (28 days) oral administration as there were no remarkable adverse alterations in the physical behaviour, neither were there significant and consistent alterations in the histopathological and haematological parameters. Further work is required to evaluate its mutagenic, teratogenic and carcinogenic effects.

Acknowledgement

We appreciate the help retendered by the technical staff of Department of Pharmacology and therapeutics, Ahmadu Bello University.

Conflict of interest

The authors declare no conflict of interest.

References

Abdoun, S., Hassan, T. I., Gaber, D. A., & El- Sharekh, A. (2019). Antidepressant activity of A. hierochuntica L. effervescent granules using forced swimming test. *Journal of Innovations in Pharmaceutical and Biological Sciences (JIPBS), 6*(2), 38–44. http://www.jipbs.com/VolumeArticle

s/FullTextPDF/450_JIPBSV6I206.pdf

Abubakar , K., Danjuma , N. M., Maiha , B. B., Anuka, . J. A., Magaji , M. G. & Malami, S. (2020). In Vitro and in Vivo Antioxidant Effect of the Stem Bark Extract of Pseudocedrela kotschyi in Pentylenetetrazole-kindled Rats"., Nigerian Journal of Pharmaceutical and Applied Science Research. *Nigerian Journal of Pharmaceutical and Applied Science Research*, *5*(3), 7–15. /www.nijophasr.net/index.php/nijophasr/article/view/138

Ozkan, A. (2012). Morphological properties and chemical compositions of some sesame (Sesamum indicum L.) populations cultivated in Kilis, Turkey. *African Journal of Agricultural Reseearch*, *7*(19), 3029–3033. https://doi.org/10.5897/ajar11.2245

Aprioku, J. S. (2017). Effects of Aqueous Bryophyllum pinnatum Leaf Extract on Haematological , Renal and Sperm Indices in Wistar Rats. *Indian Journal of Pharmaceutical Sciences*, *79*(July 2017), 521–526.

Aprioku, J. S., & Obianime, A. W. (2014). Evaluation of the Effects of Citrus aurantifolia (Lime) Juice in Lead-induced Hematological and Testicular Toxicity in Rats. *Pharmacologia*, *5*(1), 36–41. https://doi.org/10.5567/pharmacologia.2014.36.41

Asare, F., Sẗrsrud, S., & Simŕn, M. (2012). Meditation over medication for irritable bowel syndrome? on exercise and alternative treatments for irritable bowel syndrome. *Current Gastroenterology Reports*, *14*(4), 283–289. https://doi.org/10.1007/s11894-012-0268-2

Ashafa, A. O. T., Orekoya, L. O., & Yakubu, M. T. (2012). Toxicity profile of ethanolic extract of Azadirachta indica stem bark in male Wistar rats. *Asian Pacific Journal of Tropical Biomedicine*, *2*(10), 811–817. https://doi.org/10.1016/S2221-1691(12)60234-2

Bawa, B., Pateh, U. U., Hassan, H. S. & Yaro, A. H. (2012). Phytochemical and Central Nervous System Activity Study of Alysicarpus glumaceaus. *Biotropic Research International Journal*, *3*(1), 20–24.

Bekalo, T. H., Woodmatas, S. D., & Woldemariam, Z. A. (2009). An ethnobotanical study of medicinal plants used by local people in the lowlands of Konta Special Woreda, southern nations, nationalities and peoples regional state, Ethiopia. *Journal of Ethnobiology and Ethnomedicine*, *15*. https://doi.org/10.1186/1746-4269-5-26

Betancourt-Alonso, M. A., Orihuela, A., Aguirre, V., Vázquez, R., & Flores-Pérez, I. (2011). Changes in behavioural and physiological parameters associated with Taenia pisiformis infection in rabbits (Oryctolagus cuniculus) that may improve early detection of sick rabbits. *World Rabbit Science*, *19*(1), 21–30. https://doi.org/10.4995/wrs.2011.801

Bisi-Johnson, M. A., Obi, C. L., Kambizi, L., & Nkomo, M. (2010). A survey of indigenous herbal diarrhoeal remedies of O.R. Tambo district, Eastern Cape Province, South Africa. *African Journal of Biotechnology*, *9*(8), 1245–1254. https://doi.org/10.5897/AJB09.1475

Burkill, H. M. .(1985). *The useful plants of West Tropical Africa* vol. 4

(2nd ed.). Published by Royal Botanic Gardens, Kew, Richmond, Surrey TW8 3AE. 17

Chen, Q., Xue, Y., & Sun, J. (2013). Kupffer cell-mediated hepatic injury induced by silica nanoparticles in vitro and in vivo. *International Journal of Nanomedicine*, *8*, 1129–1140. https://doi.org/10.2147/IJN.S42242

CIRAD. (2010). CIRAD-Centre de Cooperation international en recherché agronomique pour le development (French Agricultural Research Centre for International Development) (Accessed on 19/07/2020).

Klaassen, P. C. (2013). Principles of Toxicology. Casarett and Doull's Toxicology: *The Basic Science of Poisons*. 5th ed. McGraw-Hill. 13.

Dukku, A. M. (2017). Emerging Perspectives on Drugs of Abuse : A Focus on Gadagi Consumption in Kano , Nigeria. *Advances in Psychology and Neuroscience*, *2*(1), 7–14. https://doi.org/10.11648/j.apn.s.2017020201.12

Etim, N. N. (2014). Haematological Parameters and Factors Affecting Their Values. *Agricultural Science*, *2*(1), 37–47. https://doi.org/10.12735/as.v2i1p37

Gandhare, B., Kavimani, S., & Rajkapoor, B. (2013). Acute and Subacute Toxicity Study of Methanolic Extract of *ceiba pentandra* (Linn.) Gaertn. on Rats. *Journal of Scientific Research*, *5*(2), 315–324. https://doi.org/10.3329/jsr.v5i2.11800

Ghosh, J., & Acharya, A. (2011). Cluster ensembles. *Wiley Interdisciplinary Reviews: Data Mining and Knowledge Discovery*, *1*(4), 305–315. https://doi.org/10.1002/widm.32

Gilani, A. H., & Atta-ur-Rahman. (2005). Trends in ethnopharmacology. *Journal of Ethnopharmacology*, *100*(1–2), 43–49. https://doi.org/10.1016/j.jep.2005.06.001

Harizal, S. N., Mansor, S. M., Hasnan, J., Tharakan, J. K. J., & Abdullah, J. (2010). Acute toxicity study of the standardized methanolic extract of *Mitragyna speciosa* Korth in Rodents. *Journal of Ethnopharmacology*, *131*(2), 404–409. https://doi.org/10.1016/j.jep.2010.07.013

Jatsa B. H, Gipwe, N., Tienga, E., Bertin, J., Fassi, K., Moaboulou, C., Dongmo, C., Dongo, E., Kamtchouing, P., & Tchuente, L. T. (2019). Efficacy of *Ozoroa pulcherrima* Schweinf methanolic extract against Schistosoma mansoni-induced liver injury in mice. *Journal of Traditional and Complementary Medicine*, *9*, 304–311. https://doi.org/10.1016/j.jtcme.2017.08.009

Jurcik, T., Chentsova-Dutton, Y. E., Solopieieva-Jurcikova, I., & Ryder, A. G. (2013). Russians in treatment: The evidence base supporting cultural adaptations. *Journal of Clinical Psychology*, *69*(7), 774–791. https://doi.org/10.1002/jclp.21971

Kakooza-Mwesige, A. (2015). The importance of botanical treatments in traditional societies and challenges in developing countries. *Epilepsy and Behavior*, *52*, 297–307. https://doi.org/10.1016/j.yebeh.2015.06.017

Khan, F., Magaji, M., Aguye, I., Hussaini, I., Hamza, A., Olorukooba, A., Sani, M., & Maje, I. (2021). Phytochemical profiling of the

bioactive principles of Alysicarpus glumaceus (Vahl) DC. aerial parts. *İstanbul Journal of Pharmacy*, *51*(2), 228–238. https://doi.org/10.26650/istanbuljpharm.2020.0071

Mensah, L.K.M., Komlaga, G., D. Forkuo, A., Firempong, C., K. Anning, A., & A. Dickson, R. (2019). Toxicity and Safety Implications of Herbal Medicines Used in Africa. *Herbal Medicine*. https://doi.org/10.5772/intechopen.72437

Lorke, D. (1983). A New Approach to Practical Acute Toxicity Testing. *Archieves of Toxicology*, 275–287.

Melillo, A. (2007). Rabbit Clinical Pathology. *Journal of Exotic Pet Medicine*, *16*(3), 135–145. https://doi.org/10.1053/j.jepm.2007.06.002

Msomi, N. Z., & Simelane, M. B. (2018). Herbal Medicine. In (Ed.), Herbal Medicine. IntechOpen. https://doi.org/10.5772/intechopen.72816.

Mukinda, J. T., & Eagles, P. F. K. (2010). *Acute and sub-chronic oral toxicity profiles of the aqueous extract of Polygala fruticosa in female mice and rats*. *128*, 236–240. https://doi.org/10.1016/j.jep.2010.01.022

Obianime, A. W., Ahiwe, N. J., & Aprioku, J. S. (2010). Effects of vitamins C and E pretreatments on cadmiuminduced serum levels of some biochemical and hormonal parameters in the female guinea pig. *African Journal of Biotechnology*, *9*(39), 6582–6587. https://doi.org/10.5897/AJB10.220

OECD. (2008). *Test No. 407 OECD Guideline for Testing of Chemicals. Repeated Dose 28-Day Oral Toxicity Study in Rodents*, OECD Guidelines for the Testing of Chemicals, Section 4, OECD Publishing, Paris, https://doi.org/10.1787/9789264070684-en.

Olson, H., Betton, G., Robinson, D., Thomas, K., Monro, A., Kolaja, G., Lilly, P., Sanders, J., Sipes, G., Bracken, W., Dorato, M., & Deun, K. Van. (2000). *Concordance of the Toxicity of Pharmaceuticals in Humans and in Animals*. *67*, 56–67. https://doi.org/10.1006/rtph.2000.1399

Ouédraogo, Y., Guissou, I. P., & Nacoulma, O. G. (2007). Biological and toxicological study of aqueous root extract from Mitragyna inermis (Willd oktze) rubiaceae. In *International Journal of Pharmacology* (Vol. 3, Issue 1, pp. 80–85). https://doi.org/10.3923/ijp.2007.80.85

Pandya, P. . (2009). *A study of the weed flora of some cultivated fields of Bharuch district. (Unpublished doctorate thesis). Saurashtra University, Porbandar-India.*

Pearce, E. L., Poffenberger, M. C., Chang, C. H., & Jones, R. G. (2013). Fueling immunity: Insights into metabolism and lymphocyte function. *Science*, *342*(6155). https://doi.org/10.1126/science.1242454

Peters, C., Muñoz, B., Sepúlveda, F. J., Urrutia, J., Quiroz, M., Luza, S., De Ferrari, G. V., Aguayo, L. G., & Opazo, C. (2011). Biphasic effects of copper on neurotransmission in rat hippocampal neurons. *Journal of Neurochemistry*, *119*(1), 78–88. https://doi.org/10.1111/j.1471-4159.2011.07417.x

Prasanth, K.M., Suba, V., Ramireddy, B. and Srinivasa, B.P. (2015). Acute and Subchronic Oral Toxicity Assessment of the Ethanolic Extract of the Root of *Oncoba spinosa* (Flacourtiaceae) in Rodents; *Tropical Journal of Pharmaceutical Research*; 14(10): 1849-1855

Ragavendran, P., Sophia, D., Arul Raj, C., & Gopalakrishnan, V. K. (2011). *Functional Group Analysis of various extracts of Aerva lanata (L.,) by FTIR Spectrum CANCER BIOLOGY View project*. *January*. https://www.researchgate.net/publication/215547192

ReportLinkers. (2022). *Global Herbal Medicine Industry*. (reportlinker.com) . (Accessed on 20/01/22).

Rhiouani, H., El-Hilaly, J., Israili, Z. H., & Lyoussi, B. (2008). Acute and sub-chronic toxicity of an aqueous extract of the leaves of Herniaria glabra in rodents. *Journal of Ethnopharmacology*, *118*(3), 378–386. https://doi.org/10.1016/j.jep.2008.05.009

Antwi-Baffour, S. (2014). The Place of Traditional Medicine in the African Society: The Science, Acceptance and Support. *American Journal of Health Research*, *2*(2), 49. https://doi.org/10.11648/j.ajhr.20140202.13

Tucci, S. A. (2010). Phytochemicals in the control of human appetite and body weight. *Pharmaceuticals*, *3*(3), 748–763. https://doi.org/10.3390/ph3030748

Vasisht, K., & Kumar, V. (2004). *Compendium of Medicinal and Aromatic Plants*. 1: Africa. Trieste: ICS-UNIDO. 34-36. https://lib.ugent.be/catalog/rug01:000824107

Vongtau, H. O., Abbah, J., Mosugu, O., Chindo, B. A., Ngazal, I. E., Salawu, A. O., Kwanashie, H. O., & Gamaniel, K. S. (2004). Antinociceptive profile of the methanolic extract of Neorautanenia mitis root in rats and mice. *Journal of Ethnopharmacology*, *92*(2–3), 317–324. https://doi.org/10.1016/j.jep.2004.03.014

World Health Organization (2002) Promoting Rational Use of Medicines: Core Components. Geneva: WHO, 2002 (WHO Policy Perspectives on Medicines n°5) (WHO/ EDM/2002.3). http:www.who.int/ medicines/ (Accessed on 22/01/22)

Yakubu, D. P., Mostyn, A., Hyatt, M. A., Kurlak, L. O., Budge, H., Stephenson, T., & Symonds, M. E. (2007). Ontogeny and nutritional programming of mitochondrial proteins in the ovine kidney, liver and lung. *Reproduction*, *134*(6), 823–830. https://doi.org/10.1530/REP-07-0155